

REVIEW ARTICLE

What Is Evidence-Based About Myofascial Chains: A Systematic Review



Jan Wilke, MA, Frieder Krause, MA, Lutz Vogt, PhD, Winfried Banzer, PhD, MD

From the Department of Sports Medicine, Goethe University Frankfurt, Frankfurt/Main, Germany.

Abstract

Objective: To provide evidence for the existence of 6 myofascial meridians proposed by Myers based on anatomic dissection studies.

Data Sources: Relevant articles published between 1900 and December 2014 were searched in MEDLINE (PubMed), ScienceDirect, and Google Scholar.

Study Selection: Peer-reviewed human anatomic dissection studies reporting morphologic continuity between the muscular constituents of the examined meridians were included. If no study demonstrating a structural connection between 2 muscles was found, articles on general anatomy of the corresponding body region were targeted.

Data Extraction: Continuity between 2 muscles was documented if 2 independent investigators agreed that it was reported clearly. Also, 2 independent investigators rated methodologic quality of included studies by means of a validated assessment tool (Quality Appraisal for Cadaveric Studies).

Data Synthesis: The literature search identified 6589 articles. Of these, 62 articles met the inclusion criteria. The studies reviewed suggest strong evidence for the existence of 3 myofascial meridians: the superficial back line (all 3 transitions verified, based on 14 studies), the back functional line (all 3 transitions verified, based on 8 studies) and the front functional line (both transitions verified, based on 6 studies). Moderate-to-strong evidence is available for parts of the spiral line (5 of 9 verified transitions, based on 21 studies) and the lateral line (2 of 5 verified transitions, based on 10 studies). No evidence exists for the superficial front line (no verified transition, based on 7 studies).

Conclusions: The present systematic review suggests that most skeletal muscles of the human body are directly linked by connective tissue. Examining the functional relevance of these myofascial chains is the most urgent task of future research. Strain transmission along meridians would both open a new frontier for the understanding of referred pain and provide a rationale for the development of more holistic treatment approaches.

Archives of Physical Medicine and Rehabilitation 2016;97:454-61

© 2016 by the American Congress of Rehabilitation Medicine

Treatments of fascial tissues have become increasingly popular in musculoskeletal disorders.¹⁻⁵ This might be because of recent histologic findings. The discovery of contractile cells, free nerve endings, and mechanoreceptors suggests that fascia in contrast with prior assumptions plays a proprioceptive and mechanically active role.⁶⁻¹³ Numerous therapists who address fascia orientate themselves to concepts of myofascial chains. Such approaches originate from the assumption that the muscles of the human body do not function as independent units. Instead, they are regarded as part of a tensegrity-like, body-wide network, with fascial structures acting as linking components. Because fascia can transmit tension,^{14,15} and in view of its proprioceptive and nociceptive

functions, existence of myofascial meridians could be responsible for disorders and pain radiating to remote anatomic structures. Myers¹⁶ defined 11 myofascial meridians connecting distant parts of the body by means of muscles and fascial tissues (fig 1). The central rule for the selection of a meridian's components is a direct linear connection between 2 muscles. For instance, a part of the superficial back line (table 1) is suggested to be formed by the biceps femoris and erector spinae muscles both being linked by means of the sacrotuberous ligament and lumbar fascia. Even if the biceps femoris also displayed a structural continuity to the gluteus maximus, this connection would not be considered part of the meridian because of its curved, nonlinear course. Although used and referred to in several studies,¹⁷⁻²² the myofascial meridians are based on anecdotal evidence from practice and have never been verified. Confirming body-wide direct morphologic

Disclosures: none.

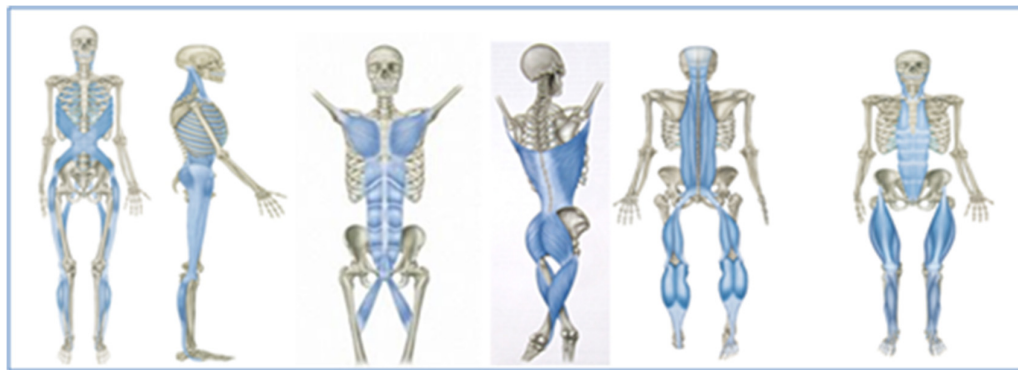


Fig 1 The 6 examined myofascial meridians (from left to right: spiral line, lateral line, front functional line, back functional line, superficial back line, and superficial front line). Adapted with permission. These figures were published in Myers TW. *Anatomy trains: myofascial meridians for manual and movement therapists*. 3rd ed. New York: Churchill Livingstone; 2014. Copyright Elsevier.

Table 1 Soft tissue components of the included myofascial meridians

Myofascial Meridian	Soft Tissue Components
Superficial back line	<ul style="list-style-type: none"> • Plantar fascia • Achilles tendon/M. gastrocnemius • Hamstrings (M. biceps femoris, M. semite-ndinosus, M. semimembranosus) • Sacrotuberous ligament • Lumbar fascia/erector spinae
Superficial front line	<ul style="list-style-type: none"> • Toe extensors, m. tibialis anterior, anterior crural department • Subpatellar tendon • M. rectus femoris/quadriceps • M. rectus abdominis • M. sternalis/sternochondral fascia • M. sternocleidomastoideus
Back functional line	<ul style="list-style-type: none"> • M. vastus lateralis • M. gluteus maximus • Lumbar fascia • M. latissimus dorsi
Front functional line	<ul style="list-style-type: none"> • M. adductor longus • M. rectus abdominis • M. pectoralis major
Spiral line	<ul style="list-style-type: none"> • Lumbar/erector spinae • Sacrotuberous ligament • M. biceps femoris • M. peroneus longus • M. tibialis anterior • M. tensor fasciae latae, iliotibial tract • M. obliquus abdominis internus • M. obliquus abdominis externus • M. serratus anterior • M. rhomboideus major and minor • M. splenius capitis and cervicis
Lateral line	<ul style="list-style-type: none"> • M. peroneus longus and brevis, lateral crural compartment • Iliotibial tract/gluteus medius • M. tensor fasciae latae • M. gluteus maximus • M. obliquus abdominis externus and internus • M. intercostalis externus and internus • M. splenius capitis/M. sternocleidomastoid

Adapted with permission from Churchill Livingstone.¹⁶

continuity between muscle and fascial tissue would therefore yield both an empirical background for such trials and an argument for practitioners to take treatment of complete meridians into consideration. This review aimed to provide evidence for 6 of the myofascial meridians based on anatomic dissection studies.

Methods

The present systematic review adhered to the Preferred Reporting Items for Systematic Reviews and Meta-Analyses guidelines.²³ Two independent investigators performed a systematic literature research. The targeted myofascial meridians were the superficial back line, superficial front line, lateral line, spiral line, back functional line, and front functional line (see table 1 and fig 1). For each transition of these meridians, peer-reviewed anatomic dissection studies (published 1900–2014) reporting myofascial continuity between the involved muscles were searched. Animal studies and case reports were excluded; the same applied to articles in languages other than German and English.

Relevant publications were identified using MEDLINE (PubMed; searched with Medical Subject Headings), ScienceDirect, and Google Scholar. Search algorithms for PubMed and ScienceDirect were of more general character (for algorithms see

Table 2 Databases and algorithms for the literature research

Database	Search Algorithm
PubMed	((“cadaver”[Mesh]) AND (“anatomy”[Mesh])) AND (“Fascia”[Mesh]) OR ((myofascial OR aponeurotic OR fascial) AND (continuity OR decussation OR interdigitation OR expansion OR extension))
ScienceDirect	cadaver AND (fascia OR myofascial OR aponeurotic OR fascial) AND (continuity OR decussation OR interdigitation OR expansion OR extension)
Google Scholar	(dissection) AND (“obliquus internus” AND “obliquus externus”) AND (continuity OR expansion OR extension OR fuses OR merges OR blends)

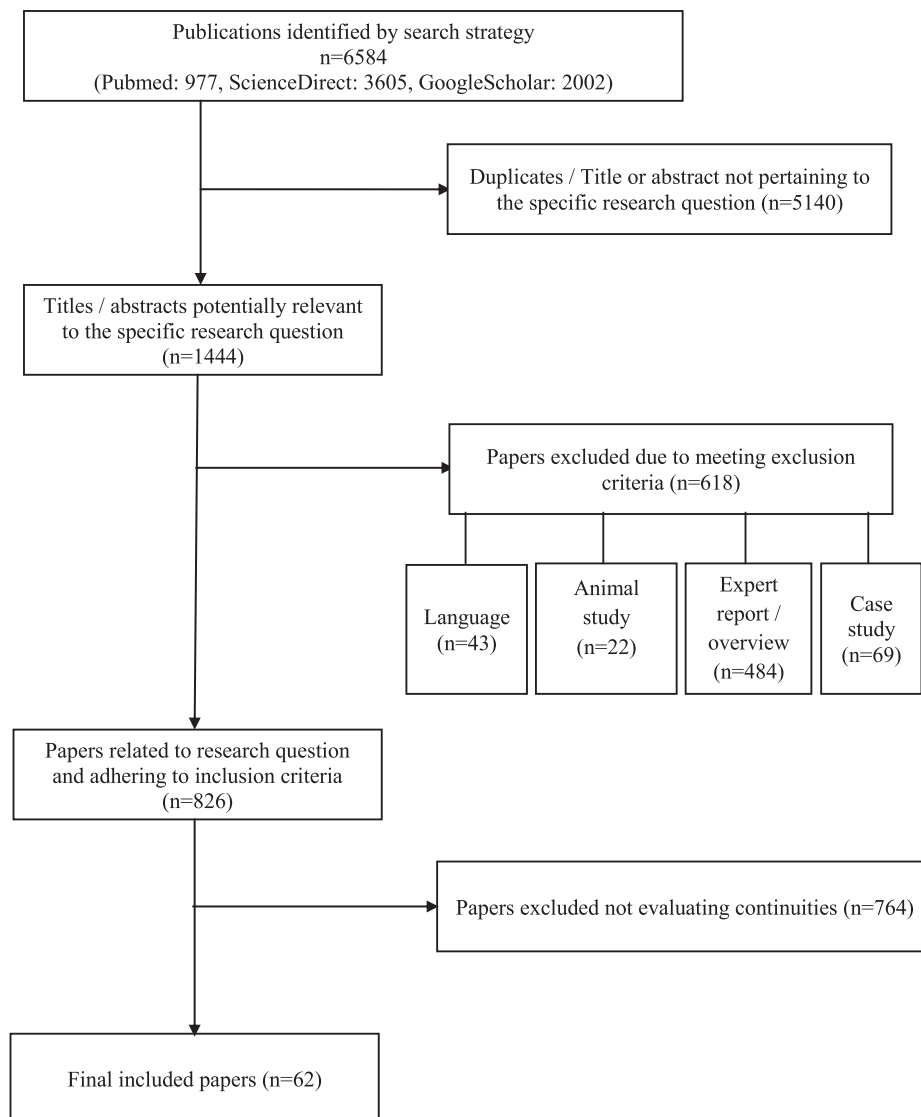


Fig 2 Flowchart displaying the literature research.

table 2), and a more specific free-text search including concrete names of the supposedly connected muscles was performed in Google Scholar. Here, the first 100 hits for each transition of the corresponding meridian were screened. If the initial literature research using the aforementioned procedure with 3 databases did not yield any results for a specific transition, dissection studies describing the general anatomy of the corresponding body region were targeted and screened for the myofascial connection. Additionally, the reference lists of all detected studies were checked. Data extraction was carried out by 2 independent investigators, and a continuity was only documented if both agreed that it was reported clearly.

The methodologic quality of the enclosed studies was evaluated by means of a scale (Quality Appraisal for Cadaveric Studies), which has recently been proven to be a reliable and valid instrument.²⁴ The scale encompasses a checklist of 13 dichotomous

items, and each was scored with either 0 (no/not stated) or 1 (yes/clearly present) point. The quality score is calculated in percent. For the scores, 0% to 20% indicates poor methodologic quality, 21% to 40% indicates fair methodologic quality, 41% to 60% indicates moderate methodologic quality, 61% to 80% indicates substantial methodologic quality, and 81% to 100% indicates excellent methodologic quality. Ratings were done by 2 independent researchers. In case of disagreement, a third reviewer casted the decisive vote. For each meridian and its respective transitions, evidence was classified as strong (consistent findings among multiple high-quality studies), moderate (consistent findings among multiple low-quality studies and/or 1 high-quality study), limited (1 low-quality study), conflicting (inconsistent findings among multiple studies), or not existent (no studies available), according to the recommendations of the Cochrane Collaboration Back Review Group.²⁵

Table 3 Included studies and morphologic details for the examined transitions

Myofascial Meridian	Transition	Studies (n)	Consistency	Studies on General Anatomy (n)	Description
Superficial back line	Plantar fascia-gastrocnemius	4 (72)	25/72	NA	Although Kamel, ²⁶ Stecco, ⁹ and colleagues report continuity in all examined cases, Snow, ²⁷ Kim, ²⁸ and colleagues state that the link diminishes with increasing age.
	Gastrocnemius-hamstrings	5 (57)	51/52	NA	Four studies ²⁹⁻³² report the semitendinosus to be linked to gastrocnemius, whereas 1 study ³³ found a link between the semimembranosus and gastrocnemius.
	Hamstrings-lumbar fascia/erector spinae	5 (122)	BF: 99/122	NA	Martin ³⁴ reports fusion of all hamstrings and erector spinae via the SL. Sato, ³⁵ van Wingerden, ³⁶ Woodley, ³⁷ and colleagues state that the BF blends with the SL in all cases. Vleeming et al ³⁸ report continuity for 41%.
Superficial front line	Toe extensors/tibialis anterior-rectus femoris	0 (NA)	NA	2 (27)	No studies confirming continuity were found. Two studies ^{39,40} on general anatomy did not yield indications for a morphologic link.
	Rectus femoris-rectus abdominis	0 (NA)	NA	NA	This transition is only mechanical therefore, no literature research was performed for this transition.
	Rectus abdominis-sternalis	0 (NA)	NA	5 (496)	No studies confirming continuity were found. Five studies ⁴¹⁻⁴⁵ on general anatomy did not yield indications for a morphologic link.
	Sternalis-sternocleidomastoideus	0 (NA)	NA	5 (496)	No studies confirming continuity were found. Five studies ⁴¹⁻⁴⁵ on general anatomy did not yield indications for a morphologic link.
Back functional line	Latissimus-lumbar fascia	3 (60)	40/40	NA	All 3 studies ⁴⁶⁻⁴⁸ reported the latissimus to fuse with the lumbar fascia at the superficial lamina of the posterior layer.
	Lumbar fascia-gluteus maximus	5 (68)	58/58	NA	Similar to the latissimus, all studies ⁴⁷⁻⁵¹ reported the gluteus maximus to fuse with the lumbar fascia at the superficial lamina of the posterior layer.
	Gluteus maximus-vastus lateralis	2 (46)	42/46	NA	Although Stern ⁵² states continuity in all examined cases, Stecco et al ⁴⁹ observed a fusion of both structures in 2 of 6 specimens.
Front functional line	Pectoralis major-rectus abdominis	3 (51)	51/51	NA	Three studies ⁵³⁻⁵⁵ observed fusion of the pectoralis major fascia and the contralateral rectus abdominis in each specimen.
	Rectus abdominis-adductor longus	3 (37)	37/37	NA	According to 3 studies, ^{15,56,57} a clear continuity of the adductor longus to the contralateral rectus sheath was visible in all examined cases.
Spiral line	Splenius capitis-rhomboideus minor	0 (NA)	NA	2 (19)	Although no study reporting direct continuity was found, Johnson et al ⁵⁸ indicate a decussation of fibers, and Mercer and Bogduk ⁵⁹ report collinear orientation of fibers, suggesting a possible fusion of both muscles.
	Rhomboideus-serratus anterior	3 (69)	4/4	NA	The fusion of the rhomboideus major and serratus anterior is stated in 3 studies. ⁶⁰⁻⁶² A morphologic connection of the rhomboideus minor is reported only by 2 articles. ^{61,63}
	Serratus anterior-external abdominal oblique	3 (68)	40/40	NA	The authors of 3 studies ^{62,64,65} describe intersections or interdigitations of both muscles at the lateral arch of the 5th–10th rib.
	External-internal abdominal oblique	5 (417)	245/245	NA	According to 5 studies, ⁶⁶⁻⁷⁰ the external abdominal oblique sends aponeurotic extensions to the contralateral internal oblique.
	Internal abdominal oblique-tensor fasciae latae	0 (NA)	NA	2 (40)	No studies confirming continuity were found. Also, studies on general anatomy did not yield any indications for a morphologic link. ^{71,72}

(continued on next page)

Table 3 (continued)

Myofascial Meridian	Transition	Studies (n)	Consistency	Studies on General Anatomy (n)	Description
	Tensor fasciae latae-tibialis anterior	0 (NA)	NA	3 (90)	No studies confirming continuity were found. Also, studies on general anatomy did not yield any indications for a morphologic link. ⁷³⁻⁷⁵
	Tibialis anterior-peroneus longus	0 (NA)	NA	3 (132)	No studies confirming continuity were found. Also, studies on general anatomy ⁷⁶⁻⁷⁸ did not yield any indications for a morphologic link.
	Peroneus longus-biceps femoris	3 (44)	23/23	NA	El Gharbawy et al ^{79,80} in 2 studies observed the biceps femoris to send aponeurotic fibers to the lateral surface of the peroneus longus, and Marshall et al ⁸¹ describe the middle expansion of the biceps femoris blending with the peroneus fascia.
	Biceps femoris-erector spinae	5 (73)	50/63	NA	As stated for the superficial backline, evidence is conflicting. Although Sato et al ³⁵ report continuity in all cases, Vleeming et al ³⁸ found both structures to fuse only in half of the examined specimen.
Lateral line	Peroneals-iliotibial tract	0 (NA)	NA	2 (47)	No studies confirming continuity were found. Also, studies on general anatomy did not indicate a morphologic link; however, Vieira et al ⁷³ stated that the iliotibial tract extends to the crural fascia.
	Iliotibial tract-gluteus maximus/tensor fasciae latae	5 (61)	NA	NA	Five studies ^{8,49,50,82,83} found a consistent connection of the gluteus maximus/tensor fasciae latae to the iliotibial tract.
	Gluteus maximus/tensor fasciae latae-abdominal obliques	1 (29)	NA	NA	One study ⁸⁴ reported the external oblique to fuse with fascia lata whose caudal continuation is tensor fasciae latae. ⁸⁵ No study stated a link of gluteus maximus to the lateral abdominals.
	Abdominal obliques-intercostals	0 (NA)	NA	2 (80)	No studies confirming continuity were found. Two studies ^{86,87} on general anatomy did not yield indications for a morphologic link.
	Intercostals-splenius capitis/sternocleidomastoideus	0 (NA)	NA	2 (80)	No studies confirming continuity were found. Two studies ^{86,87} on general anatomy did not yield indications for a morphologic link.

NOTE. Values in parentheses are the cumulative number of subjects. Consistency: Continuity observed in share of all cumulative subjects, not reported by all studies.

Abbreviations: BF, biceps femoris; NA, not applicable; SL, sacrotuberous ligament.

Results

The initial literature research yielded 6584 publications. After removing duplicates and articles not pertaining to the research question, exclusion criteria were applied. The resulting sample was comprised of 62 studies (fig 2). The findings for each meridian, including detailed information about characteristics of the appendant transitions, are displayed in table 3. Methodologic quality of the included studies is shown in table 4.

Strong evidence exists for all transitions of the superficial back line (based on 14 studies), back functional line (based on 8 studies), and front functional line (based on 6 studies). With regard to the spiral line (moderate evidence for 5 of 9 transitions, based on 21 studies) and the lateral line (moderate-to-strong evidence for 2 of 5 transitions, based on 10 studies), findings were ambivalent. No evidence from anatomic dissection studies are available for the superficial front line (no verified transition, based on 7 studies).

Discussion

The present systematic review provides relevant information for movement therapists and strength and conditioning coaches. It demonstrates that fascia, besides recently discovered features, such as pain perception and stiffness regulation, connects the skeletal muscles forming a body-wide web of myofascial chains. Extensive structural continuity was clearly verified for 3 of the 6 examined meridians (superficial back line, back functional line, front functional line). In addition, findings were at least ambivalent with respect to the lateral line and spiral line. The fact that we could only confirm half of both lines' transitions does not neglect their existence. Most of the reviewed studies did not specifically search for continuities, mentioning them only as a subordinate finding. Because clinicians and anatomists show increasing interest in fascia, it is well possible that future, more focused research will verify the remaining myofascial links.⁸⁸ In contrast with the solid evidence for these 5 meridians, doubts have to be raised about the

Table 4 Number and quality of included studies reporting myofascial continuity between the constituents of the meridians

Myofascial Meridian	Total	Excellent	Substantial	Moderate	Fair	Poor
Superficial back line	14	1	4	7	2	0
Superficial front line	0 (7)	0	(7)	0	0	0
Back functional line	8	1	3	4	0	0
Front functional line	7	3	3	0	1	0
Spiral line	13 (8)	0	2 (3)	10 (5)	1	0
Lateral line	7 (4)	0	6	1 (3)	0	(1)

NOTE. Studies on general anatomy are displayed in parentheses (only searched if no papers reporting continuity were detected).

existence of the superficial front line. There is no structural connection between the rectus femoris muscle and rectus abdominis muscle. Also, the sternalis muscle, which is suggested to be the cranial continuation of the rectus abdominis muscle, exists only in a small percentage of the population.⁴¹⁻⁴⁴ Even if present, it does not fuse consistently with the rectus abdominis muscle.⁴¹

The practical relevance of the present research is 2-fold. First, the existence of myofascial meridians might help to explain the phenomenon of referred pain, which often occurs in nonspecific disorders. For example, myofascial trigger points of the calf have been shown to elicit pain that radiates to the sole of the foot and the dorsal thigh.⁸⁹ Because this projection pattern corresponds to the course of the superficial back line, it might represent the morphologic substrate. A second aspect relates to therapy and training of the musculoskeletal system. Direct morphologic continuity between adjacent muscles provides the empirical background to extend diagnostic and therapeutic focus beyond a single anatomic structure. Treatment according to myofascial meridians could be effective in reducing low back pain. Several studies have shown that patients with low back pain display reduced hamstring flexibility.⁹⁰⁻⁹³ Because of the direct morphologic relation of the hamstrings and low back region (both are part of the superficial back line), relieving tension of the posterior thigh muscles could be a conceivable approach to alleviate pain. Overload injuries in competitive sports represent another entity of pathologies which possibly occur because of the presence of myofascial meridians. Recent studies indicate that tightness of the gastrocnemius and hamstrings are associated with plantar fasciitis.⁹⁴⁻⁹⁶ Because both muscles and the plantar aponeurosis belong to the superficial back line, they might represent a target of exercise therapy. Finally, groin pain or athletic pubalgia is suggested to be provoked by a tight adductor longus and a weak rectus abdominis,^{97,98} which according to our results are directly connected in the front functional line. The tightening of the adductor may therefore develop because of communication with the rectus abdominis via the described linkage.

Study limitations

Although our review yields solid evidence for the existence of myofascial chains, several aspects call for further study. Future research should be dedicated to the presence of the meridians, which could not be evidenced entirely in this work. Another issue relates to the function of regional specializations, which so far remains unclear. Depending on its localization, fascia in general exhibits substantial differences concerning thickness, amount of elastic fibers,¹¹ and adherence to the underlying muscle.⁸ Also, the number of connecting fibers is not uniform and shows considerable variation for different transitions.²⁷ This holds particular significance because the structures linking the muscular stations of

the meridians encompass tendinous, aponeurotic, and ligamentous tissue as well as the deep fascia. Finally, it is of utmost importance to elucidate the functional significance of the myofascial chains because the capability for strain transfer represents the decisive criterion to justify treatment of meridians. Although the available evidence points toward existence of tensile transmission via myofascial pathways, most experimental research was carried out in vitro using cadavers.^{14,15,36} Randomized, controlled in vivo studies are warranted to draw more precise assumptions on the significance of myofascial chains for the movement system.

Conclusions

Although the concept of myofascial meridians is widely used in exercise therapy and osteopathic medicine, the scientific basis for the proposed connections is still a matter of debate. The present review provides first systematic evidence based on cadaveric dissection studies. Although there is strong empirical support for the existence of the superficial back line, back functional line, and front functional line, evidence is ambivalent with regard to the spiral line and lateral line respectively poor for the superficial front line. Within its borders, the system of myofascial meridians represents a promising approach to transfer tensegrity principles into practice. Therapists may use the myofascial chains as a conclusive orientation, but they should be aware that the functional implications remain to be studied.

Keywords

Connective tissue; Fascia; Meridians; Myofascial pain syndromes; Rehabilitation

Corresponding author

Jan Wilke, MA, Department of Sports Medicine, Goethe University Frankfurt, Ginnheimer Landstraße 39 | 60487 Frankfurt/Main, Germany. *E-mail address:* wilke@sport.uni-frankfurt.de.

References

- Engel RM, Brown BT, Swain MS, Lystad RP. The provision of chiropractic, physiotherapy and osteopathic services within the Australian private health-care system: a report of recent trends. *Chiropr Man Therap* 2014;22:3.
- de las Peñas CF, Sohrbeck Campo M, Fernández Carnero J, Miangolarra Page JC. Manual therapies in myofascial trigger

- point treatment: a systematic review. *J Body Mov Ther* 2005;9:27-34.
3. Ndetan H, Evans MW, Hawk C, Walker C. Chiropractic or osteopathic manipulation for children in the United States: An Analysis of Data from the 2007 National Health Interview Survey. *J Alt Complement Med* 2012;18:347-53.
 4. Ong C, Doll H, Bodeker G, Stewart-Brown S. Use of osteopathic or chiropractic services among people with back pain: a UK population survey. *Health Soc Care Community* 2004;12:265-73.
 5. Wardle JL, Sibbritt DW, Adams J. Referrals to chiropractors and osteopaths: a survey of general practitioners in rural and regional New South Wales, Australia. *Chiropr Man Therap* 2013;21:5.
 6. Bhattacharya V, Barooah P, Nag T, Chaudhuri G, Bhattacharya S. Detailed microscopic analysis of deep fascia of lower limb and its surgical implication. *Indian J Plast Surg* 2010;43:135-40.
 7. Staubesand J, Li Y. The fine structure of the fascia cruris with particular attention to epi- and intrafascial nerves [German]. *Manuelle Medizin* 1996;34:196-200.
 8. Stecco A, Macchi V, Masiero S, et al. Pectoral and femoral fasciae: common aspects and regional specializations. *Surg Radiol Anat* 2009;31:35-42.
 9. Stecco C, Corradin M, Macchi V, et al. Plantar fascia anatomy and its relationship with Achilles tendon and paratenon. *J Anat* 2013;223:665-76.
 10. Stecco C, Gagey O, Belloni A, et al. Anatomy of the deep fascia of the upper limb. Second part: study of innervation. *Morphologie* 2007;91:38-43.
 11. Stecco C, Porzionato A, Lancerotto L, et al. Histological study of the deep fasciae of the limbs. *J Bodyw Mov Ther* 2008;12:225-30.
 12. Tesarz J, Hoheisel U, Wiedenhofer B, Mense S. Sensory innervation of the thoracolumbar fascia in rats and humans. *Neuroscience* 2011;194:302-8.
 13. Yahia L, Rhalmi S, Newman N, Isler M. Sensory innervation of human thoracolumbar fascia. An immunohistochemical study. *Acta Orthop Scand* 1992;63:195-7.
 14. Barker PJ, Briggs CA, Bogeski G. Tensile transmission across the lumbar fasciae in unembalmed cadavers: effects of tension to various muscular attachments. *Spine* 2004;29:129-38.
 15. Norton-Old KJ, Schache AG, Barker PJ, Clark RA, Harrison SM, Briggs CA. Anatomical and mechanical relationship between the proximal attachment of adductor longus and the distal rectus sheath. *Clin Anat* 2013;26:522-30.
 16. Myers TW. *Anatomy trains: myofascial meridians for manual and movement therapists*. 3rd ed. New York: Churchill Livingstone; 2014.
 17. Ajimsha M, Daniel B, Chithra S. Effectiveness of myofascial release in the management of chronic low back pain in nursing professionals. *J Bodyw Mov Ther* 2014;18:273-81.
 18. Behnam A, Mahyar S, Ezzati K, Rad SM. The use of dry needling and myofascial meridians in a case of plantar fasciitis. *J Chir Med* 2014;13:43-8.
 19. Hyouk HI, Kang JH. The immediate effects of passive hamstring stretching exercises on the cervical spine range of motion and balance. *J Phys Ther Sci* 2013;25:113-6.
 20. Hyouk HI, Hyun KJ. The effect of forward head on ankle joint range of motion and static balance. *J Phys Ther Sci* 2012;24:925-7.
 21. Lumbroso D, Ziv E, Vered E, Kalichman L. The effect of kinesio tape application on hamstring and gastrocnemius muscles in healthy young adults. *J Bodyw Mov Ther* 2014;18:130-8.
 22. Weisman MH, Haddad M, Lavi N, Vulfsons S. Surface electromyographic recordings after passive and active motion along the posterior myofascial kinematic chain in healthy male subjects. *J Bodyw Mov Ther* 2013;18:452-61.
 23. Liberati A, Altman DG, Tetzlaff J, et al. The PRISMA statement for reporting systematic reviews and meta-analyses of studies that evaluate health care interventions: explanation and elaboration. *Ann Intern Med* 2009;151:W65-94.
 24. Wilke J, Krause F, Niederer D, Engeroff T, Vogt L, Banzer W. Appraising the quality of cadaveric studies. Validation of the QUACS scale. *J Anat* 2015;226:440-6.
 25. van Tulder M, Furlan A, Bombardier C, Bouter L. Updated method guidelines for systematic reviews in the Cochrane collaboration back review group. *Spine* 2003;28:1290-9.
 26. Kamel R, Sakla FB. Anatomical compartments of the sole of the human foot. *Anat Rec* 1961;140:57-60.
 27. Snow SW, Bohne WH, DiCarlo E, Chang VK. Anatomy of the Achilles tendon and plantar fascia in relation to the calcaneus in various age groups. *Foot Ankle Int* 1995;16:418-21.
 28. Kim PJ, Richey J, Wissman LR, Steinberg JS. The variability of the Achilles tendon insertion: a cadaveric examination. *J Foot Ankle Surg* 2010;49:417-20.
 29. Candal-Couto JJ, Deehan DJ. The accessory bands of gracilis and semitendinosus: an anatomical study. *Knee* 2003;10:325-8.
 30. Kolodychuk LB. Clinically significant anatomy of gracilis and semitendinosus tendon insertions. *Clin J Sport Med* 1992;2:276-8.
 31. Reina N, Abbo O, Gomez-Brouchet A, Chiron P, Moscovici J, Laffosse J. Anatomy of the bands of the hamstring tendon: how can we improve harvest quality? *Knee* 2013;20:90-5.
 32. Tuncay I, Kucuker H, Uzun I, Karalezli N. The fascial band from semitendinosus to gastrocnemius: the critical point of hamstring harvesting: an anatomical study of 23 cadavers. *Acta Orthop* 2007;78:361-3.
 33. Mochizuki T, Akita K, Muneta T, Sato T. Pes anserinus: layered supportive structure on the medial side of the knee. *Clin Anat* 2004;17:50-4.
 34. Martin BF. The origins of the hamstring muscles. *J Anat* 1968;102:345-52.
 35. Sato K, Nimura A, Yamaguchi K, Akita K. Anatomical study of the proximal origin of hamstring muscles. *J Orthop Sci* 2012;17:614-8.
 36. van Wingerden JP, Vleeming A, Snijders CJ, Stoeckart R. A functional-anatomical approach to the spine-pelvis mechanism: interaction between the biceps femoris muscle and the sacrotuberous ligament. *Eur Spine J* 1993;2:140-4.
 37. Woodley SJ, Mercer SR. Hamstring muscles: architecture and innervation. *Cells Tissues Organs* 2005;179:125-41.
 38. Vleeming A, Stoeckart R, Snijders C. The sacrotuberous ligament: a conceptual approach to its dynamic role in stabilizing the sacroiliac joint. *Clin Biomech* 1989;4:201-3.
 39. Andrikoula S, Tokis A, Vasiliadis HS, Georgoulis A. The extensor mechanism of the knee joint: an anatomical study. *Knee Surg Sports Traumatol Arthrosc* 2006;14:214-20.
 40. Waligora AC, Johanson NA, Hirsch BE. Clinical anatomy of the quadriceps femoris and extensor apparatus of the knee. *Clin Orthop Relat Res* 2009;467:3297-306.
 41. Barlow RN. The sternalis muscle in American whites and negroes. *Anat Rec* 1935;61:413-26.
 42. Jeleu L, Georgiev G, Surchev L. The sternalis muscle in the Bulgarian population: classification of sternales. *J Anat* 2001;199:359-63.
 43. Motabagani MA, Sonalla A, Abdel-Meguid E, Bakheit MA. Morphological study of the uncommon rectus sterni muscle in German cadavers. *East Afr Med J* 2004;81:130-3.
 44. Saeed M, Murshid KR, Rufai AA, Elsayed SE, Sadiq MS. Sternalis. An anatomic variant of chest wall musculature. *Neurosciences* 2002;7:248-55.
 45. Silveira D, Sousa KM, Siqueira SL, et al. Sternalis muscle: an anatomic variation of the anterior chest wall. *J Morphol Sci* 2012;29:76-8.
 46. Bogduk N, Macintosh JE. The applied anatomy of the thoracolumbar fascia. *Spine* 1984;9:164-70.
 47. Macintosh JE, Bogduk N. The morphology of the lumbar erector spinae. *Spine* 1987;12:658-68.
 48. Vleeming A, Pool-Goudzwaard AL, Stoeckart R, van Wingerden JP, Snijders CJ. The posterior layer of the thoracolumbar fascia. Its function in load transfer from spine to legs. *Spine* 1995;20:753-8.

49. Stecco A, Gilliar W, Hill R, Fullerton B, Stecco C. The anatomical and functional relation between gluteus maximus and fascia lata. *J Bodyw Mov Ther* 2013;17:512-7.
50. Barker P, Hapuarachchi K, Ross J, Sambaiew E, Ranger T, Briggs C. Anatomy and biomechanics of gluteus maximus and the thoracolumbar fascia at the sacroiliac joint. *Clin Anat* 2014;27:234-40.
51. Vleeming A, Pool-Goudzwaard AL, Hammudoghlu D, Stoeckart R, Snijders CJ, Mens JM. The function of the long dorsal sacroiliac ligament: its implication for understanding low back pain. *Spine* 1996;21:556-62.
52. Stern JT. Anatomical and functional specializations of the human gluteus maximus. *Am J Phys Anthropol* 1972;36:315-39.
53. Jinde L, Jianliang S, Xiaoping C, et al. Anatomy and clinical significance of pectoral fascia. *Plast Reconstr Surg* 2006;118:1557-60.
54. Stecco A, Macchi V, Stecco C, et al. Anatomical study of myofascial continuity in the anterior region of the upper limb. *J Bodyw Mov Ther* 2009;13:53-62.
55. Stecco A, Masiero S, Macchi V, Stecco C, Porzionato A, De Caro R. The pectoral fascia: anatomical and histological study. *J Bodyw Mov Ther* 2009;13:255-61.
56. Davis JA, Stringer MD, Woodley SJ. New insights into the proximal tendons of adductor longus, adductor brevis and gracilis. *Br J Sports Med* 2012;46:871-6.
57. Robinson P, Salehi F, Grainger A, et al. Cadaveric and MRI study of the musculotendinous contributions to the capsule of the symphysis pubis. *Am J Roentgenol* 2007;188:W440-5.
58. Johnson GM, Zhang M, Jones DG. The fine connective tissue architecture of the human ligamentum nuchae. *Spine* 2000;25:5-9.
59. Mercer SR, Bogduk N. Clinical anatomy of ligamentum nuchae. *Clin Anat* 2003;16:484-93.
60. Bharihoke V, Gupta M. Muscular attachments along the medial border of the scapula. *Surg Radiol Anat* 1986;8:71-3.
61. Nasu H, Yamaguchi K, Nimura A, Akita K. An anatomic study of structure and innervation of the serratus anterior muscle. *Surg Radiol Anat* 2012;34:921-8.
62. Vu P, Guedon C, Gehanno P, Andreassian B. Anatomic basis of serratus anterior muscle flap transposition. *Surg Radiol Anat* 1988;10:173-85.
63. Williams GR Jr, Shakil M, Klimkiewicz J, Iannotti JP. Anatomy of the scapulothoracic articulation. *Clin Orthop Relat Res* 1999;(359):237-46.
64. Cuadros CL, Driscoll CL, Rothkopf DM. The anatomy of the lower serratus anterior muscle: a fresh cadaver study. *Plast Reconstr Surg* 1995;95:93-9.
65. Peiper C, Junge K, Prescher A, Stumpf M, Schumpelick V. Abdominal musculature and the transversalis fascia: an anatomical viewpoint. *Hernia* 2004;8:376-80.
66. Anson BJ, McVay CB. The anatomy of the inguinal and hypogastric regions of the abdominal wall. *Anat Rec* 1938;70:211-25.
67. Askar OM. Surgical anatomy of the aponeurotic expansions of the anterior abdominal wall. *Ann R Coll Surg Engl* 1977;59:313-21.
68. McVay CB, Anson BJ. Composition of the rectus sheath. *Anat Rec* 1940;77:213-25.
69. Mwachaka P. Variations in the pattern of formation of the abdominis rectus muscle sheath among Kenyans. *Int J Morphol* 2009;27:1025-9.
70. Rizk NN. A new description of the anterior abdominal wall in man and mammals. *J Anat* 1980;131:373-85.
71. Ramasastry SS, Tucker JB, Swartz WM, Hurwitz D. The internal oblique muscle flap. An anatomic and clinical study. *Plast Reconstr Surg* 1984;73:721-3.
72. Ramasastry SS, Granick MS, Futrell JW. Clinical anatomy of the internal oblique muscle. *J Reconstr Microsurg* 1986;2:117-22.
73. Vieira EL, Vieira EA, da Silva RT, Berlefin PA, Abdalla RJ, Cohen M. An anatomic study of the iliotibial tract. *Arthroscopy* 2007;23:269-74.
74. Terry GC, LaPrade RF. The posterolateral aspect of the knee: anatomy and surgical approach. *Am J Sports Med* 1996;24:732-9.
75. Terry GC, Hughston JC, Norwood LA. The anatomy of the iliotibial band and iliotibial tract. *Am J Sports Med* 1986;14:39-45.
76. Patil V, Frisch NC, Ebraheim NA. Anatomical variations in the insertion of the peroneus (fibularis) longus tendon. *Foot Ankle Int* 2007;28:1179-82.
77. Shyamsundar S, Wazir A, Allen PE. Variations in the insertion of peroneus longus tendon-a cadaver study. *Foot Ankle Surg* 2012;18:293-5.
78. Brenner E. Insertion of the tendon of the tibialis anterior muscle in feet with and without hallux valgus. *Clin Anat* 2002;15:217-23.
79. El Gharbawy RM. Relations of the common peroneal nerve to the insertion of biceps femoris and origin of peroneus longus. *Alex J Med* 2006;42:817-28.
80. El Gharbawy RM, Skandalakis LJ, Skandalakis JE. Protective mechanisms of the common fibular nerve in and around the fibular tunnel: a new concept. *Clin Anat* 2009;22:738-46.
81. Falvey EC, Girgis FG, Zelko RR. The biceps femoris tendon and its functional significance. *J Hand Surg [Am]* 1972;54:1444-50.
82. Al-Hayani A. The functional anatomy of hip abductors. *Folia Morphol (Warsz)* 2009;68:98-103.
83. Falvey EC, Clark RA, Franklyn-Miller A, Bryant AL, Briggs C, McCrory PR. Iliotibial band syndrome: an examination of the evidence behind a number of treatment options. *Scand J Med Sci Sports* 2010;20:580-7.
84. Doyle JF. The superficial inguinal arch. A re-assessment of what has been called the inguinal ligament. *J Anat* 1971;12:297-304.
85. Flack N, Nicholson H, Woodley S. The anatomy of the hip abductor muscles. *Clin Anat* 2014;27:241-53.
86. Naples V, Rothschild B. Do ribs actually have a bare area? A new analysis. *J Comp Hum Biol* 2011;62:368-73.
87. Siddiqi MA, Mullick AN. On the anatomy of intercostal spaces in man and certain other mammals. *J Anat* 1935;69:350-5.
88. van der Waal J. The architecture of the connective tissue in the musculoskeletal system- an often overlooked functional parameter as to proprioception in the locomotor apparatus. *Int J Ther Massage Bodywork* 2009;2:9-23.
89. Travell JG, Simons DG. Myofascial pain and dysfunction: the trigger point manual: the lower extremities. Baltimore: Lippincott Williams & Wilkins; 1992.
90. Feldman DE. Risk factors for the development of low back pain in adolescence. *Am J Epidemiol* 2001;154:30-6.
91. Hultman G, Saraste H, Ohlsen H. Anthropometry, spinal canal width, and flexibility of the spine and hamstring muscles in 45-55-year-old men with and without low back pain. *J Spinal Disord* 1992;5:245-53.
92. Mierau D, Cassidy JD, Yong-Hing K. Low-back pain and straight leg raising in children and adolescents. *Spine* 1989;14:526-8.
93. Salminen JJ, Maki P, Oksanen A, Pentti J. Spinal mobility and trunk muscle strength in 15-year-old schoolchildren with and without low-back pain. *Spine* 1992;17:405-11.
94. Bolívar YA, Munuera PV, Padillo JP. Relationship between tightness of the posterior muscles of the lower limb and plantar fasciitis. *Foot Ankle Int* 2013;34:42-8.
95. Harty J, Soffe K, O'Toole G, Stephens MM. The role of hamstring tightness in plantar fasciitis. *Foot Ankle Int* 2005;26:1089-92.
96. Labovitz JM, Yu J, Kim C. The role of hamstring tightness in plantar fasciitis. *Foot Ankle Spec* 2011;4:141-4.
97. Anderson K, Strickland SM, Warren R. Hip and groin injuries in athletes. *Am J Sports Med* 2001;29:521-33.
98. Morales-Conde S, Socas M, Barranco A. Sportsmen hernia: what do we know? *Hernia* 2010;14:5-15.