



Contents lists available at ScienceDirect

Journal of Equine Veterinary Science

journal homepage: www.j-evs.com



Original Research

The Equine Hindlimb Proximal Suspensory Ligament: an Assessment of Health and Function by Means of Its Damping Harmonic Oscillator Properties, Measured Using an Acoustic Myography System: a New Modality Study

Jillian Costello Chavers^a, A. Kent Allen^a, Waqas Ahmed^b,
Lene Høeg Fuglsang-Damgaard^b, Adrian P. Harrison^{b,*}

^a Virginia Equine Imaging, Middleburg, VA

^b Department of Veterinary and Animal Sciences, Faculty of Health & Medical Sciences, University of Copenhagen, Denmark



ARTICLE INFO

Article history:

Received 3 August 2018
Received in revised form
12 September 2018
Accepted 13 September 2018
Available online 19 September 2018

Keywords:

CURO
Acoustic myography
Equine
Suspensory desmitis
Lameness

ABSTRACT

Enhanced, objective systems for evaluation of the proximal suspensory ligament are needed to hasten appropriate diagnosis and treatment of injury. This study compared the *in vivo* acoustic signals generated by healthy and injured hindlimb proximal suspensory ligaments (PSLs) in horses and determined if an acoustic myography (AMG) system was an acceptable tool to aid in diagnosis. Complete lameness evaluations were performed on 96 horses either with a history or suspicion of hindlimb lameness. Acoustic myography signals were acquired with the aid of a CURO from the hindlimbs after a moving evaluation and before additional procedures. For all horses with hindlimb lameness, diagnostic analgesia and appropriate imaging were performed to reach a causative diagnosis for the lameness. The signals obtained were analyzed by blinded evaluators *via* CURO algorithms and scored from 0 to 10 (poor to optimal). Eighty-five horses in total provided adequate diagnostic data. Of these, 15 (17.7%) horses were clinically sound, 48 (56.5%) horses had clinical evidence of PSL injury, 4 (4.7%) horses were recovering from prior PSL injuries, and 18 (21.1%) horses had another cause of hindlimb lameness. There was a significant difference ($P > .001$) in the CURO score between horses with evidence of PSL injury and all other groups. Correlations showed that PSLs were healthy with a score >5 (60% of SOUND horses; 87% of PSL-TREATED), had low-level injury at scores 2.5–4.5, and severe injuries at scores <2 . It is concluded that AMG is a promising diagnostic tool to detect injuries of the proximal suspensory ligament in horses.

© 2018 The Authors. Published by Elsevier Inc. This is an open access article under the CC BY-NC-ND license (<http://creativecommons.org/licenses/by-nc-nd/4.0/>).

Animal welfare/ethical statement: The study was approved by the management and ownership of Virginia Equine Imaging and had informed consent of the owners. There was no ethical issue in this study because all the subjects were healthy. Moreover, the measuring equipment used complied with both CE and FCC regulations and was noninvasive in its nature. The study was carried out according to the guidelines laid out in the Helsinki Declaration (<https://www.wma.net/policies-post/wma-declaration-of-helsinki-ethical-principles-for-medical-research-involving-human-subjects/>) so as to protect owners names, gender, and other personal data.

Conflict of interest statement: A.P.H. is currently trying to commercialize the CURO system (CURO.diagnostics) and is establishing a company to cover the costs of future development. The CURO system was provided to Virginia Equine Imaging at no cost. Virginia Equine Imaging and its staff and doctors were not compensated for this study.

* Corresponding author at: Adrian P. Harrison, Faculty of Health & Medical Sciences, Copenhagen University, Grønnegaardsvej 7, DK-1870, Frederiksberg C, Denmark.

E-mail address: adh@sund.ku.dk (A.P. Harrison).

1. Introduction

Injury to the proximal suspensory ligament (PSL) is common in most types of athletic horses and can account for up to 46% of all limb injuries [1–4]. This injury is likely more common than we know in the hindlimb, as diagnosis and imaging continues to be complex due to the intricate tarsal and metatarsal anatomy and concurrent pathologies that may exist [5–12]. A noninvasive, quick, and accurate means of assessing the health and functionality of the suspensory ligament could hasten diagnosis and treatment, hopefully reducing lay-up time and loss in the equine industry. Recent studies have evaluated ultrasound-based techniques in the assessment of tendon and ligament injury with application of elastography and acoustoelastography, which relates changes in echogenicity observed during deformation of a tendon from an

<https://doi.org/10.1016/j.jevs.2018.09.006>

0737-0806/© 2018 The Authors. Published by Elsevier Inc. This is an open access article under the CC BY-NC-ND license (<http://creativecommons.org/licenses/by-nc-nd/4.0/>).

unloaded to a loaded state to the mechanical properties of the tissue [13–15]. These techniques show promise for tracking improvements in tendon and ligament healing, but appear to have similar sensitivity to ultrasound alone for detecting the injury. Furthermore, these techniques often require sedation of the subject and cannot be performed during a moving evaluation.

Ligaments and tendons are generally known to be periodically vibrating elastic structures. Indeed, a recent *in vivo* study using ultrasound imaging has shown that tendon tissue undergoes a pattern of rapid lengthening and shortening during the stance phase of running [16]. Such a change has a clear benefit in terms of the return of elastic energy stored in the connective tissue structure to associated muscles, making such units largely free of metabolic costs [17]. However, these structures also act as damping harmonic oscillators, in much the same way that shock absorbers on vehicles reduce the vibrations associated with traveling over rough ground [18].

Acoustic myography (AMG) is a biomechanical method in that it evaluates tissues that generate pressure waves, for example, contracting muscle [19–21]. The AMG technique was originally designed to measure the pressure waves generated by voluntary muscle contractions and record them, using a flat piezoceramic sensor to convert pressure waves into microvolts. However, it has recently been discovered by the authors that these sensors can also be used to record the shock waves that are transmitted through the suspensory tissue after foot impact and as such monitor the ability of the suspensory system to act as a damping harmonic oscillator. Damping opposes the back and forth motion of a harmonic oscillator, and critical damping is defined as the condition in which the damping of an oscillator results in it returning as quickly as possible to its resting position [22]. The PSL acts as just such a harmonic oscillator, such that damage to the PSL consequently affects its ability to damp ground reaction forces, which can be seen in the recorded signal characteristics.

Thus AMG as a technique is capable of detecting pressure waves within a tissue, pressure waves that arise from an external source. In this particular study, the recordings were of the absorption of the ground reaction force (GRF) by the suspensory system, acting as a harmonic oscillator. The purpose of this study was to determine if AMG, using sensors placed over the skin on the plantarproximal metatarsus, could accurately detect the damping function of the PSL during both walk and trot. It was hypothesized that the parameters recorded using AMG could be used to assess the degree of injury and functionality of the hindlimb PSL of horses.

2. Materials and Methods

All horses presenting for a second opinion or a referral in clinic lameness evaluation scheduled with Dr Allen at Virginia Equine Imaging over a period of 7 months were candidates for inclusion. Ninety-six horses were used for data collection. The population consisted of 69 (71.9%) geldings, 26 (27.1%) mares, and 1 stallion (1.0%), of which there were 71 (74.0%) warmbloods, 15 (15.6%) Thoroughbreds, 6 (6.2%) Thoroughbred crosses, 2 (2.1%) ponies, and 2 (2.1%) draft crosses. The average (mean \pm standard deviation) mass was 533 ± 55 kg and age was 10 ± 3 years with ranges of 363–681 kg and 3–17 years, respectively.

All horses received complete physical and lameness evaluations. Any palpable abnormalities (thickening, swelling, etc.) were recorded. The horses were evaluated by experienced lameness clinicians (A.K.A. and J.C.C.) moving at the walk and trot on a straight line on a firm rubber surface, and walk, trot, and canter lunging on a 20-m circle to the left and right on a firm, crushed compacted bluestone surface. Horses with subtle lameness or complaints by riders of poor performance were also evaluated

lunging with a weighted surcingle (27 kg) and ridden under saddle over a sand arena surface. Flexions of both distal forelimbs, upper hindlimbs, and distal hindlimbs were performed on the firm rubber surface. After completion of the baseline lameness evaluation, the CURO sensors were applied (Fig. 1) and recordings performed at the walk and trot over the firm rubber surface.

Over 3 to 5 minutes, four separate consecutive recordings at the walk on a 30-m straight line, followed by two recordings at a trot on the straight line, and two final recordings at the walk on the straight line were performed. The data were compiled in WAV format and any identifying or clinical information except for right or left hindlimb designation was removed. The data were analyzed by blinded evaluators (W.A., L.H.C., and A.P.H.). After completion of data collection, the lameness evaluations continued with diagnostic analgesia and imaging performed as dictated by results of the evaluation to reach a final diagnosis.

Based on the diagnosis obtained with evaluators unaware of final results of the CURO scores, the horses were assigned to one of the four groups: (1) horses with proximal suspensory ligament desmopathy or enthesopathy (PSL-INJURY $n = 48$, 56.5%); (2) horses with lameness that did not block to the proximal suspensory ligament (NON-PSL $n = 18$, 21.1%); (3) horses with no clinical or performance history of lameness (SOUND $n = 15$, 17.7%); and (4) sound horses currently recovered from PSL injury and in full work (PSL-TREATED $n = 4$, 4.7%). In this study, TREATED represents horses that received focused extracorporeal shock wave therapy for a predefined period and at set intervals or surgery (neurectomy of the deep branch of the lateral plantar nerve), in combination with carefully monitored exercise of gradually increasing duration and intensity as part of a successful rehabilitation program developed at Virginia Equine Imaging (for details contact Dr Kent Allen).




Fig. 1. CURO sensors, placement, rigging, and user interface.

2.1. Acoustic Myography Recordings

A CURO unit (MyoDynamik ApS, Frederiksberg C, Denmark) sampling at 4 kHz, attached to a 20-mm piezoelectric crystal CURO sensor (MyoDynamik ApS, Frederiksberg C, Denmark) coated with acoustic gel was used for PSL recordings (Fig. 1) [23,24]. Based on the anatomical location where the largest volume of muscle tissue would be, sensors were placed 2 cm below the head of the lateral splint bone either on the skin over the superficial digital flexor tendon on the plantar aspect of the metatarsus, or the skin over the deep digital flexor tendon on the plantaromedial aspect of the metatarsus on each hind leg using a self-adhesive bandage (Co-Plus LF; BSN medical GmbH, Hamburg, Germany; Sher-Light; Covidien, Mansfield, MA, USA) or a flexible bandage (Snogg AS, 4671 Kristiansand, Norway). Signals detected at each location were equivalent (data not shown), although it should be noted that the signal generally from the PSL is much larger in amplitude than that recorded from either the superficial digital flexor tendon or deep digital flexor tendon (data not shown). Connecting cables were run from the sensors over the lateral aspect of the hock, over the back, and connected to the CURO unit that was placed in a small pouch mounted on a surcingle. The wires were secured with a flexible adhesive bandage (Snogg AS, 4671 Kristiansand, Norway) (Fig. 1).

The parameters determined with this device are efficiency (E-score) as well as both spatial and temporal summation expressed by the S- and T-score of the combined ESTi Score (MyoDynamik ApS, Frederiksberg C, Denmark), where the E corresponds to the periods of active/inactive function relative to the duration of the activity period of the muscle (how long the muscle is “on”), S in terms of muscle reflects the recruitment of motor units and equates to signal amplitude (how many motor units are active), or in this case, the functionality of the PSL to act as an efficient harmonic oscillator and quickly damp a GRF, and T is the motor unit firing rate or signal frequency (how fast the motor units are firing) [25]. The ESTi score is a mean of the individual scores and gives a relative ranking of fitness.

The CURO data in this study were analyzed principally in terms of their individual S parameter for each subject in a blinded fashion. The S-score was determined as the signal amplitude in relation to a full 6 dB signal (measured as approx. 1 V). For more intuitive assessment of optimal muscle function, a scale of 0–10 was adopted, where 0 was considered as 0% optimal and 10 was considered 100% optimal. To calculate the score, the measured mV amplitude was subtracted from the maximal mV amplitude that could be accurately detected. The difference was then divided by the maximal amplitude and multiplied by 10 to yield a 0–10 scoring system. By way of an example, an S-score of 8 represents a signal with a very small amplitude (approx. 0.3 V), whereas an S-score of 1 represents a relatively large amplitude signal (approx. 0.7 V). Scores were obtained by selecting a period for analysis where four to six even strides could be analyzed while the horse was moving at a steady gait and not turning, accelerating, or decelerating. Data were recollected if the horse became spooked or was otherwise exuberant. The average time required to obtain data was 3 to 5 minutes.

2.2. Statistical Analysis

Data were initially tested for a normal distribution and equal variance. Differences between means were tested for statistical significance using GraphPad InStat 3 (Version 3.0 b, 2003; Graph-Pad Inc, La Jolla, CA, USA) for Mac using an ANOVA (one way) with Tukey–Kramer multiple comparison tests. Differences between means with a *P* value > .05 were considered nonsignificant. Values are presented as the mean ± the standard deviation of the mean.

2.3. Ethics

The management and ownership of Virginia Equine Imaging approved the study design. The horse owners were informed about the study and were able to see the measuring setup, ask questions in a private setting before consenting to participate, and observe data collection. The measuring equipment, which was noninvasive, complied with both CE and FCC regulations.

3. Results

Reliable data and diagnostics were collected on 85 horses (170 limbs). Reasons for exclusion of the data on the last 11 horses included sensor malfunction, inconsistent results of diagnostic analgesia, and data corruption. The data were collated according to their assigned groups, but also in relation to the left and right hindlimbs of the horses measured. Individual diagnoses for the NON-PSL group are beyond the scope of this analysis, but are provided in Supplement 1. The mean “S” score ± standard deviation for each group was PSL-INJURY 4.3 ± 1.87, NON-PSL 6.47 ± 1.54, SOUND 5.20 ± 2.23, and PSL-TREATED 6.51 ± 1.05 at the walk, and at the trot PSL-INJURY 2.20 ± 2.17, NON-PSL 4.02 ± 2.49, SOUND 4.43 ± 2.34, and PSL-TREATED 5.95 ± 1.14. Of the 30 hindlimbs measured for the SOUND group, 33% scored higher than a 6 on the S-score. At the walk, there was a very significant difference noted for the PSL-INJURY group versus both the PSL-TREATED (*P* < .01) and NON-PSL groups (*P* < .001) (Fig. 2). There was also a significant difference between the NON-PSL versus the SOUND group (*P* < .05). No significant difference between the TREATED and the OTHER groups was detected.

In terms of trotting, a very significant overall difference was noted for the PSL-INJURY group measurements versus all groups (*P* = .0001) (Fig. 3). There were no significant differences noted between the remaining three groups at the trot.

A typical recording for a healthy PSL measurement can be seen in the upper panel of Fig. 4. It shows the signal generated by the PSL during walking, with a small amplitude signal and a compact time frame. In comparison, a typical signal from a horse with proximal suspensory ligament desmitis can be seen in the lower panel of Fig. 4. Note that on the lower trace for the right hindlimb [R] (low S-score of 4.4), it shows a large amplitude signal compared with the left hindlimb, which shows a healthy S-score signal of 8.2. Sixty percent of the SOUND group and 87% of the PSL-TREATED group scored above 5. When the PSL-INJURY group was further evaluated, there was a tendency for horses with more severe lameness and imaging abnormalities to score lower than those with mild changes as shown in Fig. 5.

4. Discussion

To the best of the authors' knowledge, this study is the first to assess the functionality of the PSL of horses during walk and trot in terms of their ability to absorb ground reaction forces, thereby measuring their efficiency as damping harmonic oscillators.

Our results reveal significant differences in scores for horses with documented PSL injury versus those without. Moreover, there was a significant difference between the PSL-INJURY and NON-PSL groups, indicating that CURO scores are not representative of lameness but of another mechanical factor of the limb. This finding is further supported by the lack of difference between the NON-PSL, SOUND, and PSL-TREATED groups. This factor is most likely the function of the proximal suspensory ligament. As a result, this is the first study to assess the functionality of the PSL of horses during walk and trot over a uniform, firm surface. Based on the results of

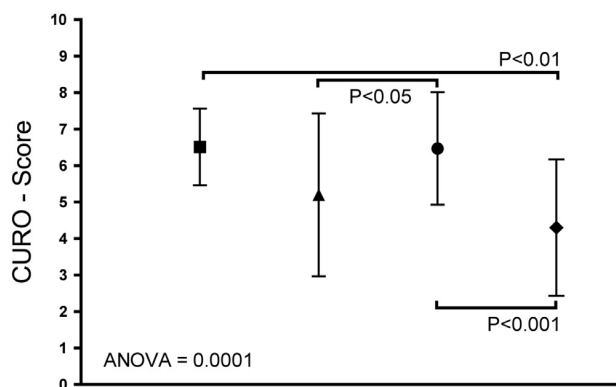


Fig. 2. A graph of the group means (\pm SD) for PSLs during periods of walk for the hindlimbs. Data are for $n = 8, 30, 36,$ and 96 PSLs for the PSL-TREATED (■), SOUND (▲), NON-PSL (●), and PSL-INJURY (◆) groups, respectively.

this study, the CURO system displays promise to help determine the health of the proximal suspensory ligament.

Anatomically, the suspensory apparatus of the hindlimbs consists of the suspensory ligament and distal sesamoidean ligaments [7,26,27]. It serves to suspend the fetlock and facilitate storage of elastic energy generated during locomotion, thus encountering large repetitive forces. Although adaptation of ligaments and tendons has been demonstrated, they do not possess the abilities necessary to accommodate sudden rapid increases in force or greatly compensate for fatigue, with the result that damage may accumulate and result in tears or complete rupture [2,3,28,29]. This damage is compounded within the hind proximal suspensory ligament in that the surrounding anatomy encases it, resulting in a compartment syndrome that compresses the vasculature and neural supply, preventing it from healing appropriately [30–32].

The muscle fibers present in the equine forelimb proximal suspensory ligament is primarily type 1 slow-twitch fibers arranged in a pinnate fashion at angles of 45° – 80° with high oxidative potential and fatigue resistance [7]. To the authors' knowledge, an equivalent detailed anatomical study in the hindlimb does not exist, but the anatomy is presumed likely to be very similar. Based on the CURO scores presented in this study, we propose that the function of the PSL muscle is likely to be one of a sensory nature. We believe that the muscle functions to detect the degree of tension in the PSL but also acts to adjust the tension of the PSL so as to

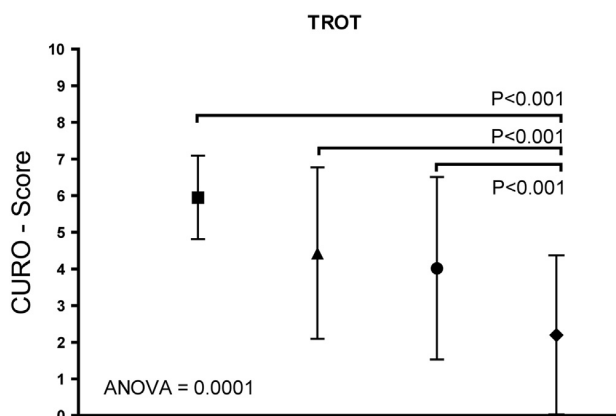


Fig. 3. A graph of the group means (\pm SD) for PSLs during periods of trot for the hindlimbs. Data are for $n = 8, 30, 36,$ and 96 PSLs for the PSL-TREATED (■), SOUND (▲), NON-PSL (●), and PSL-INJURY (◆) groups, respectively.




Fig. 4. The signal graph for six strides of a healthy horse (A) and six strides for an injured horse (B) walking on a hard surface. Signal A has a small amplitude (high S-score; 9) and is of short duration for healthy ligaments. Signal B has a greater amplitude (low S-score; 4) and is of a longer duration for low-level injury ligaments. The scale bars represent time (Sec) on the x-axis, where the interval between signals is approximately 1.5 seconds (mean stride length), and the S-score (0–10) on the y-axis, where a value of 9 equates approx. to 0.2 V and a value of 4 equates to 0.5 V.

maximize its efficiency as a harmonic oscillator. This harmonic oscillator function “damping action” is well demonstrated by comparing the signal graph of a healthy proximal suspensory ligament and an injured ligament to a graph of a generic harmonic oscillator experiencing damping (Fig. 6). By way of an example, when the muscle function of a ligament is impaired, there is a change in the recorded signal characterized by a delayed peak and a greater peak amplitude (low S-score) of that of a normal healthy ligament.

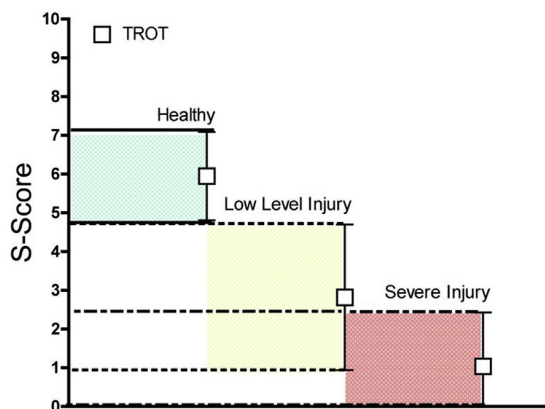
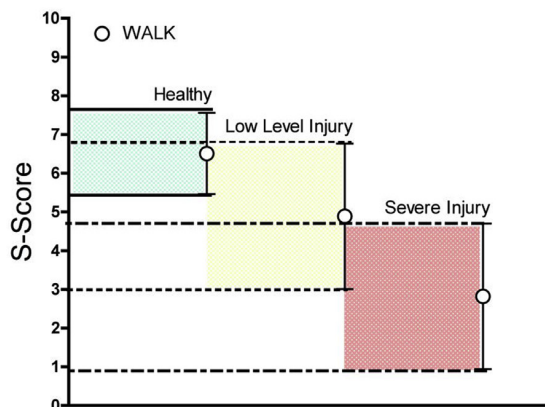


Fig. 5. A graph of recorded S-scores for PSLs, graded according to healthy (includes SOUND, PSL-TREATED, and NON-PSL groups), and low-level injury and severe injury in the PSL-INJURY group for horses both walking (upper panel) and trotting (lower panel).

A harmonic oscillator is a system that when displaced from its equilibrium position experiences a restoring force “ F ” proportional to the displacement. The inherent stiffness of the system as well as external forces eventually reduces the displacement of the system back to the baseline, and when the displacement is graphed, it appears as in Fig. 6. There is some concern that tendons and ligaments experience creep, or the lengthening of an elastic structure held under constant tension, which could modify the harmonic oscillation of the tendon or ligament [33,34]. However, increased lengthening for a given force as explained by creep would necessitate a reduction in stiffness. Recently, Farris et al, in a study of 12 male human subjects running for 30 minutes at 12 kmph on a treadmill, documented that the loading experienced during a single bout of running had no effect on the stiffness of the Achilles tendon, as measured by ultrasound imaging and kinematic data, and that its properties remained stable throughout the period of activity, a finding that argues strongly against the existence of creep in such tissue [35]. In addition, if creep was significantly present in equine tendons and ligaments, there would be an expectation for significant changes in conformation over time which is not observed, with the exclusion of degenerative suspensory ligament desmitis (DSLSD) and other collagen diseases. It is clear that an understanding of the active participation of ligaments in connection with the forces exerted on them during weight-bearing is now needed. Indeed, recordings such as those presented in this study, when analyzed in detail in terms of their characteristics (see Fig. 6), can reveal details about the functionality of the suspensory system. Such details could conceivably lead to more optimal and effective treatment of, for example, suspensory desmitis, as well as prevention of other ligament injuries; for example, early detection of the degeneration of the suspensory ligaments of horses with pituitary pars intermedia dysfunction [36], or even those with DSLSD characterized by altered expression of TGF β signaling, thought to be associated with metabolic disturbances [37].

Every effort was made to confirm a diagnosis of proximal suspensory ligament injury, or to definitively exclude it during this study. For a horse to be included in the PSL group, their lameness had to improve by 75% or greater with a deep branch of the lateral plantar nerve block or direct infiltration of the proximal suspensory ligament, have corresponding abnormalities on a diagnostic ultrasound (increased size or hypoechoic change; detailed article of the

comparison of US *cf* AMG in preparation) and/or nuclear scintigraphy, and have no significant radiographic abnormalities in the hocks or proximal metatarsus that could have contributed to the lameness observed. If there was any doubt regarding a diagnosis, the horse was either excluded from the study or was blocked again later with intent on separating out the concurrent pathologies to confirm a diagnosis. The prevalence of PSL injury detected in our group was higher than those previously introduced; however, this could be explained by the fact that most horses evaluated at this clinic are referral cases, with other causes of lameness already ruled out or treated.

The results of this study provide an almost endless supply of additional questions as is common with a novel technique. There are many variables that could likely affect scores, including footing, if scores were acquired before, during, or after exercise, and diagnostic analgesia, all of which were factors tightly controlled in this study. In addition, the observation that the PSL-TREATED group had higher scores than the SOUND group now needs to be further examined. It should be noted although that while the standard variation of the PSL-TREATED group was much smaller than that of the SOUND group, there was no significant difference between these two groups. Furthermore, it should be noted that the PSL-TREATED group represents a much smaller number of recordings, and should be treated accordingly until further data can be collated. However, this observation may indicate that not only are clinically sound horses slowly accumulating injuries to their suspensory ligaments, but also that adopted forms of PSL treatment appear efficacious.

This technology does not replace a thorough examination, diagnostic analgesia, or appropriate imaging, as a singular reliance on it will result in missed diagnoses in cases with multifactorial lameness or subclinical injury. However, it does give us a way to objectively and quickly view the function of a site of common injury, and this is a very valuable information from a preventative medicine, diagnostic, and rehabilitation point of view. Furthermore, AMG, compared with other commonly used modalities, is not only less time consuming and less expensive but also more objective and quantitative, lending more insight into the functional properties of the PSL.

Acknowledgment

The authors would like to thank the owners for their willingness and interest in connection with this study, as well as the assistance of Drs Susan Johns, Christina Russillo, Melanie Tuplin, and Zehra Gundogan during data collection; veterinary technicians Lauren Hagarty and Kianna Scott; and the visiting students who also participated.

Authors' contributions: A.K.A., J.C.C., and A.P.H. designed the study. All clinical and imaging assessments were performed by A.K.A. and J.C.C. Blinded measurements and statistical analysis were performed by W.A., L. Callesen, and A.P.H. All authors contributed to the writing of the article.

Financial disclosure: There were no sources of funding.

Supplementary Data

Supplementary data related to this article can be found at <https://doi.org/10.1016/j.jevs.2018.09.006>.

References

- [1] Murray RC, Dyson SJ, Tranquille C, Adams V. Association of type of sport and performance level with anatomical site of orthopaedic injury diagnosis. *Equine Vet J* 2006;38:411–6.

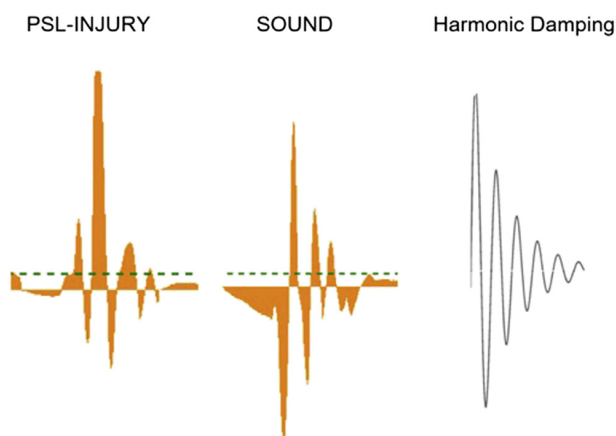


Fig. 6. An illustrative example of single steps covering a time frame of 0.06 seconds for a PSL-INJURY and SOUND horse compared alongside a generic depiction of a harmonic oscillator undergoing heavy damping (signal amplitude is not to scale for illustrative purposes). The PSL-INJURY demonstrates irregular changes in the amplitude, and a delay in the maximal signal peak, compared with SOUND, which demonstrates regular harmonic damping.

- [2] Kasashima Y, Takahashi T, Smith RKW, Goodship A E, Kuwano A, Ueno T, Hirano S. Prevalence of superficial digital flexor tendonitis and suspensory desmitis in Japanese Thoroughbred flat racehorses in 1999. *Equine Vet J* 2004;36:346–50.
- [3] Williams RB, Harkins LS, Hammond CJ, Wood JLN. Racehorse injuries, clinical problems and fatalities recorded on British racecourses from flat racing and National Hunt racing during 1996, 1997 and 1998. *Equine Vet J* 2001;33:478–86.
- [4] Hill AE, Gardner IA, Carpenter TE, Lee CM, Hitchens PL, Stover SM. Prevalence, location and symmetry of noncatastrophic ligamentous suspensory apparatus lesions in California Thoroughbred racehorses, and association of these lesions with catastrophic injuries. *Equine Vet J* 2016;48:27–32.
- [5] Selberg K. Diagnosing problems in the tarsus and proximal metatarsus: a regional approach. In: Lameness 2017 program proceedings NEAEP. Lexington, KY: American Association of Equine Practitioners, Iron Works Parkway; 2017. p. 67–72.
- [6] Dyson S, Pinilla MJ, Bolas N, Murray R. Proximal suspensory desmopathy in hindlimbs: magnetic resonance imaging, gross post-mortem and histological study. *Equine Vet J* 2018;50:159–65.
- [7] Bischofberger AS, Konar M, Ohlerth S, Geyer H, Lang J, Ueltschi G, Lischer CJ. Magnetic resonance imaging, ultrasonography and histology of the suspensory ligament origin: a comparative study of normal anatomy of Warmblood horses. *Equine Vet J* 2006;38:508–16.
- [8] Denoix JM, Bertoni L. The angle contrast ultrasound technique in the flexed limb improves assessment of proximal suspensory ligament injuries in the equine pelvic limb. *Equine Vet Educ* 2015;27:209–17.
- [9] Hinnigan G, Milner P, Talbot A, Singer E. Is anaesthesia of the deep branch of the lateral plantar nerve specific for the diagnosis of proximal metatarsal pain in the horse? *Vet Comp Orthop Traumatol* 2014;27:351–7.
- [10] Labens R, Schramme MC, Robertson ID, Thrall DE, Redding WR. Clinical, magnetic resonance, and sonographic imaging findings in horses with proximal plantar metatarsal pain. *Vet Radiol Ultrasound* 2010;51:11–8.
- [11] Dyson S, Murray R, Pinilla MJ. Proximal suspensory desmopathy in hindlimbs: a correlative clinical, ultrasonographic, gross post mortem and histological study. *Equine Vet J* 2017;49:65–72.
- [12] Gasperi D De, Dzierzak SL, Muir P, Vanderby R, Brounts SH. In vivo evaluation of effects of sedation on results of acoustoelastography of the superficial digital flexor tendons in clinically normal horses. *Am J Vet Res* 2017;78:1421–5.
- [13] Lustgarten M, Redding WR, Labens R, Morgan M, Davis W, Seiler GS. Elastographic characteristics of the metacarpal tendons in horses without clinical evidence of tendon injury. *Vet Radiol Ultrasound* 2014;55:92–101.
- [14] Lustgarten M, Redding WR, Labens R, Davis W, Daniel TM, Griffith E, Seiler GS. Elastographic evaluation of naturally occurring tendon and ligament injuries of the equine distal limb. *Vet Radiol Ultrasound* 2015;56:670–9.
- [15] Beck TW, Housh TJ, Cramer JT, Weir JP, Johnson GO, Coburn JW, Malek MH, Mielke M. Mechanomyographic amplitude and frequency responses during dynamic muscle actions: a comprehensive review. *Biomed Eng Online* 2015;4:67.
- [16] Lichtwark GA, Bougoulais K, Wilson AM. Muscle fascicle and series elastic element length changes along the length of the human gastrocnemius during walking and running. *J Biomech* 2007;40:157–64.
- [17] Ishikawa M, Pakaslahti J, Komi PV. Medial gastrocnemius muscle behavior during human running and walking. *Gait Posture* 2007;25:380–4.
- [18] Decker MJ, Dingwell JB. Can a force driven harmonic oscillator model be clinically applied to ACL reconstructed patients?. In: Proceedings of the 25th Annual International Conference of the IEEE, 2. Piscataway, NJ: Engineering in Medicine and Biology Society; 2003. p. 1788–91.
- [19] Islam MA, Sundaraj K, Ahmad RB, Ahamed NU. Mechanomyogram for muscle function assessment: a review. *PLoS One* 2013;8:e58902.
- [20] Orizio C, Gobbo M. Mechanomyography. In: Wiley Encycl Biomed Eng. New York, USA: John Wiley & Sons; 2006. p. 1–11.
- [21] Harrison AP, Danneskiold-Samsøe B, Bartels EM. Portable acoustic myography – a realistic noninvasive method for assessment of muscle activity and coordination in human subjects in most home and sports settings. *Physiol Rep* 2013;1:1–9.
- [22] Piovesan D, Pirobon A, Mussa Ivaldi FA. Critical damping conditions for third order muscle models: implications for force control. *J Biomech Eng* 2013;135:1010101–8.
- [23] Riis KH, Harrison AP. Non-invasive assessment of equine muscular function: a case study. *Open Vet J* 2013;3:80–4.
- [24] Millares EM, Bollingberg-soerensen H, Jeune SSLe. Preliminary evaluation of the effect of acupuncture on acoustic myographic recordings in five sport horses. *Am J Tradit Chin Vet Med* 2017;12:1–5.
- [25] Harrison AP. A more precise, repeatable and diagnostic alternative to surface electromyography - an appraisal of the clinical utility of acoustic myography. *Clin Physiol Funct Imaging* 2018;38:1–14.
- [26] Soffler C, Hermanson JW. Muscular design in the equine interosseus muscle. *J Morphol* 2006;267:696–704.
- [27] Shikh Alsook MK, Antoine N, Piret J, Moula N, Busoni V, Denoix JM, Gabriel A. Morphometric analyses of the body and the branches of the normal third interosseous muscle (suspensory ligament) in Standardbreds. *Anat Histol Embryol* 2013;42:461–70.
- [28] Langberg H, Ellingsgaard H, Madsen T, Jansson J, Magnusson SP, Aagaard P, Kjær M. Eccentric rehabilitation exercise increases peritendinous type I collagen synthesis in humans with Achilles tendinosis. *Scand J Med Sci Sports* 2007;17:61–6.
- [29] Coupee C, Hansen P, Kongsgaard M, Kovanen V, Suetta C, Aagaard P, Kjær M, Magnusson SP. Mechanical properties and collagen cross-linking of the patellar tendon in old and young men. *J Appl Physiol* 2009;107:880–6.
- [30] Tóth F, Schumacher J, Schramme M, Holder T, Adair HS, Donnell RL. Compressive damage to the deep branch of the lateral plantar nerve associated with lameness caused by proximal suspensory desmitis. *Vet Surg* 2008;37:328–35.
- [31] Shikh Alsook MK, Gabriel A, Salouci M, Piret J, Alzamel N, Moula N, Denoix JM, Antoine N, Baise E. Characterization of collagen fibrils after equine suspensory ligament injury: an ultrastructural and biochemical approach. *Vet J* 2015;204:117–22.
- [32] Dyson S, Blunden A, Murray R. Magnetic resonance imaging, gross post-mortem, and histological findings for soft tissues of the plantar aspect of the tarsus and proximal metatarsal region in non-lame horses. *Vet Radiol Ultrasound* 2017;58:216–27.
- [33] Ker RF, Wang XT, Pike AVL. Fatigue quality of mammalian tendons. *J Exp Biol* 2000;203:1317–27.
- [34] Maganaris CN, Paul JP. Tensile properties of the in vivo human gastrocnemius tendon. *J Biomech* 2002;35:1639–46.
- [35] Farris DJ, Trewartha G, McGuigan MP. The effects of a 30-min run on the mechanics of the human Achilles tendon. *Eur J Appl Physiol* 2012;112:653–60.
- [36] Hofberger SC, Gauff F, Thaller D, Morgan R, Keen JA, Licka TF. Assessment of tissue-specific cortisol activity with regard to degeneration of the suspensory ligaments in horses with pituitary pars intermedia dysfunction. *Am J Vet Res* 2018;79:199–210.
- [37] Luo W, Sandy J, Trella K, Gorski D, Gao S, Li J, Brounts S, Galante J, Plaas A. Degenerative suspensory ligament desmitis (DSL) in Peruvian Paso horses is characterized by altered expression of TGFβ signaling components in adipose-derived stromal fibroblasts. *PLoS One* 2016;11:1–18.