


# SCIENTIFIC REPORTS

**OPEN**

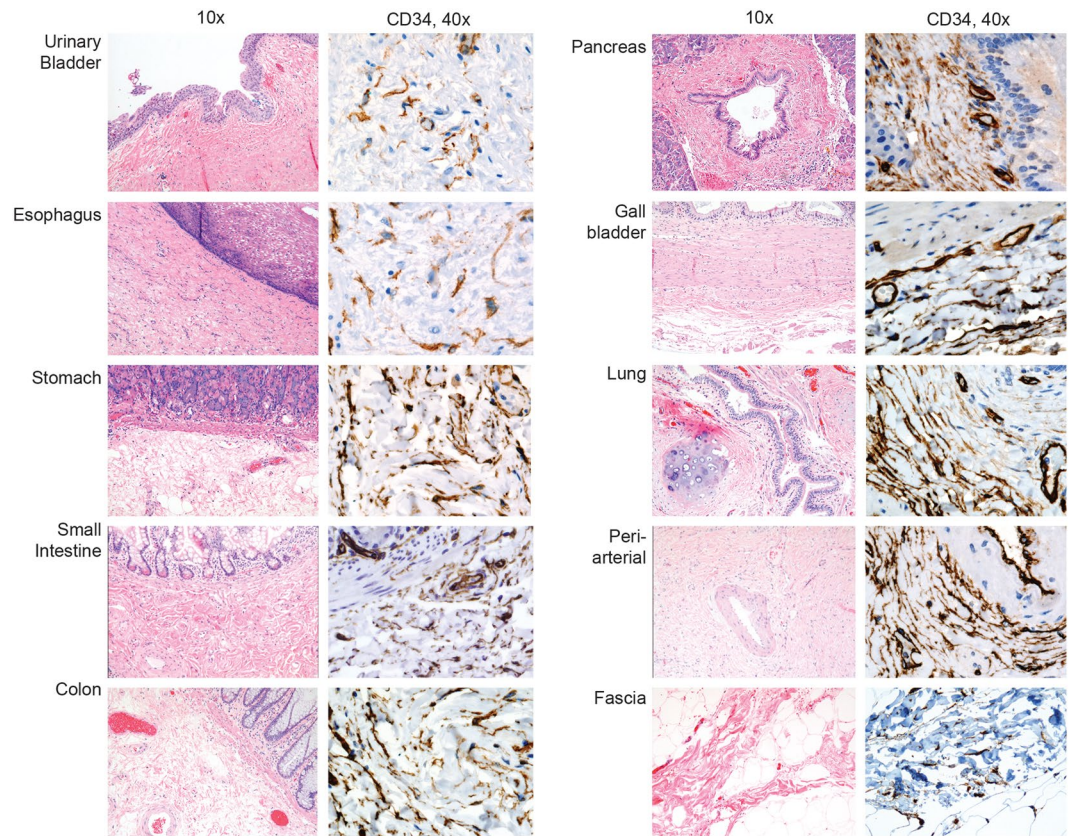
## Author Correction: Structure and Distribution of an Unrecognized Interstitium in Human Tissues

Petros C. Benias<sup>1,2</sup>, Rebecca G. Wells<sup>3,4</sup>, Bridget Sackey-Aboagye<sup>3</sup>, Heather Klavan<sup>1</sup>, Jason Reidy<sup>5</sup>, Darren Buonocore<sup>5</sup>, Markus Miranda<sup>1</sup>, Susan Kornacki<sup>6</sup>, Michael Wayne<sup>7</sup>, David L. Carr-Locke<sup>1,8</sup> & Neil D. Theise<sup>1,5,6</sup>


Correction to: *Scientific Reports* <https://doi.org/10.1038/s41598-018-23062-6>, published online 27 March 2018

The Supplementary Figure file that accompanies this Article contains an error in Supplementary Figure S1, where the Small Intestine CD34 panel was duplicated from the Gallbladder CD34 panel. The correct Figure S1 appears below as Figure 1.

<sup>1</sup>Department of Medicine, Division of Digestive Diseases, Mount Sinai Beth Israel Medical Center, Icahn School of Medicine at Mount Sinai, New York, New York, 10003, USA. <sup>2</sup>Department of Medicine, Division of Gastroenterology, Zucker School of Medicine at Hofstra/Northwell, 500 Hofstra Blvd, Hempstead, NY, 11549, USA. <sup>3</sup>Department of Medicine, Division of Gastroenterology, Perelman School of Medicine, University of Pennsylvania, Philadelphia, Pennsylvania, 19104, USA. <sup>4</sup>Department of Bioengineering and Center for Engineering MechanoBiology, School of Engineering and Applied Sciences, University of Pennsylvania, Philadelphia, Pennsylvania, 19104, USA. <sup>5</sup>Department of Pathology, Mount Sinai Beth Israel Medical Center, Icahn School of Medicine at Mount Sinai, New York, New York, 10003, USA. <sup>6</sup>Department of Pathology, New York University School of Medicine, New York, New York, 10016, USA. <sup>7</sup>Department of Surgery, Mount Sinai Beth Israel Medical Center, Icahn School of Medicine at Mount Sinai, New York, New York, 10003, USA. <sup>8</sup>The Center for Advanced Digestive Care, Weill Cornell Medicine, New York Presbyterian Hospital, 1305 York Avenue, 4th Floor, New York, New York, 10021, USA. Petros C. Benias and Rebecca G. Wells contributed equally to this work. David L. Carr-Locke and Neil D. Theise jointly supervised this work. Correspondence and requests for materials should be addressed to N.D.T. (email: [neil.theise@nyumc.org](mailto:neil.theise@nyumc.org))



**Figure 1.**

 **Open Access** This article is licensed under a Creative Commons Attribution 4.0 International License, which permits use, sharing, adaptation, distribution and reproduction in any medium or format, as long as you give appropriate credit to the original author(s) and the source, provide a link to the Creative Commons license, and indicate if changes were made. The images or other third party material in this article are included in the article's Creative Commons license, unless indicated otherwise in a credit line to the material. If material is not included in the article's Creative Commons license and your intended use is not permitted by statutory regulation or exceeds the permitted use, you will need to obtain permission directly from the copyright holder. To view a copy of this license, visit <http://creativecommons.org/licenses/by/4.0/>.

© The Author(s) 2018