



PILOT STUDY

Application of Fascial Manipulation[®] technique in chronic shoulder pain—Anatomical basis and clinical implications

Julie Ann Day, PT^{a,*}, Carla Stecco, M.D.^b, Antonio Stecco, M.D.^c

^aCentro Socio Sanitario dei Colli, Physiotherapy, Azienda Ulss 16, Via dei Colli 4, Padova, Italy

^bSection of Anatomy, Department of Human Anatomy and Physiology, University of Padova, Italy

^cPhysical Medicine and Rehabilitation Clinic, University of Padova, Italy

Received 28 March 2008; received in revised form 10 April 2008; accepted 21 April 2008

KEYWORDS

Fascia;
Musculoskeletal
dysfunction;
Manual technique;
Chronic shoulder pain;
Fascial Manipulation

Summary Classical anatomy still relegates muscular fascia to a role of contention. Nonetheless, different hypotheses concerning the function of this resilient tissue have led to the formulation of numerous soft tissue techniques for the treatment of musculoskeletal pain. This paper presents a pilot study concerning the application of one such manual technique, Fascial Manipulation[®], in 28 subjects suffering from chronic posterior brachial pain. This method involves a deep kneading of muscular fascia at specific points, termed centres of coordination (cc) and centres of fusion (cf), along myofascial sequences, diagonals, and spirals. Visual Analogue Scale (VAS) measurement of pain administered prior to the first session, and after the third session was compared with a follow-up evaluation at 3 months. Results suggest that the application of Fascial Manipulation[®] technique may be effective in reducing pain in chronic shoulder dysfunctions. The anatomical substratum of the myofascial continuity has been documented by dissections and the biomechanical model is discussed.

© 2008 Elsevier Ltd. All rights reserved.

Introduction

Shoulder pain is a common affliction that determines symptoms of pain, limited range of move-

ment and varying degrees of functional impairment. It is the third most common musculoskeletal complaint after back and neck pain. In fact, in a randomised study conducted in Holland (Picavet and Schouten, 2003), it is reported that, in 1998, an estimated 21% of the population had shoulder complaints, of which 41% had consulted their primary care physician in the previous 12 months

*Corresponding author. Tel.: +39 0498216032;

fax: +39 0498216045.

E-mail address: lavitava@gmail.com (J.A. Day).

for this problem. About 50% of patients had consulted their physician 6 months after pain onset and more than 40% had on-going pain after another 12 months. Patients with a new pain episode often reported (46%) having had previous episodes of shoulder pain.

Despite the prevalence of this complaint, there is little overall evidence to guide physiotherapy treatments, whereas there is evidence to support the use of some interventions (i.e. supervised exercises and mobilisation) only in specific and circumscribed cases (e.g. rotator cuff disorders, mixed shoulder disorders and adhesive capsulitis) (Green et al., 2003).

There is wide agreement that alterations of the deep muscle fascia could be a source of musculoskeletal dysfunctions. Despite a relative lack of well-documented information, the necessity to provide scientific explanations for numerous, highly effective manual techniques has produced a number of clinical hypotheses, some working models and a series of on-going research (Rolf, 1997; Myers, 2001; Stecco, 2004; Langevin, 2006).

Nonetheless, attempts to study the functional anatomy of deep muscular fascia can be frustrating and confusing. Long overlooked by classical anatomy, and relegated to a role of mere contention and packing, in recent years this highly innervated and intricately structured tissue is gaining increasing attention. However, only a few regions have been studied in detail, namely the thoracolumbar fascia (Gracovetsky et al., 1985; Vleeming et al., 1995; Yahia et al., 1992; Loukas et al., 2007), the iliotibial tract (Birnbau et al., 2004; Fairclough et al., 2006) and the plantar aponeurosis (Kitaoka et al., 1997; Yu, 2000).

When dealing with musculoskeletal disorders therapists are continuously faced with the dilemma of focus. What to focus on or, in other words, where best to apply massage, pressure, or friction becomes the key question when, undeniably, the shoulder, as any other joint, is part of an interrelated system and its relationship with the rest of the body is an essential part of its functionality.

One manual technique that provides a rationale for treatment of specific areas of muscular fascia, together with detailed indications for the localisation of these points, is Fascial Manipulation[®]. This paper presents a pilot study of the application of this myofascial technique in chronic shoulder pain. Our attention focused on providing plausible anatomical explanations for the results obtained. The posterior myofascial sequence of the upper limb, termed the retromotion sequence (Figure 1) is examined in detail, and its anatomical substratum is illustrated. Some of the concepts of the

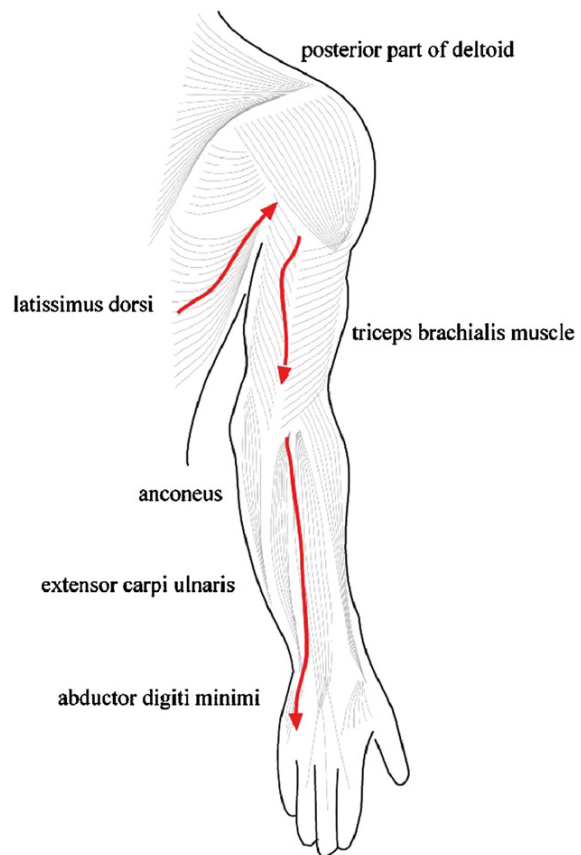


Figure 1 Retromotion myofascial sequence of upper limb.

Fascial Manipulation[®] model are discussed and possible clinical implications are considered.

The biomechanical model of the Fascial Manipulation[®] technique

The manual therapy technique known as Fascial Manipulation[®], presents a biomechanical model to decipher the role of fascia in musculoskeletal disorders considering that the myofascial system is a three-dimensional continuum. Other authors present different models that all part from this basic concept of continuity (Busquet, 1995; God-elieve, 1996; Myers, 2001). In Fascial Manipulation[®], the body is divided into 14 segments: head, neck, thorax, lumbar, pelvis, scapula, humerus, elbow, carpus, digits, hip, knee, ankle, and foot. Each body segment is served by six myofascial units (mf units) consisting of monoarticular and biarticular unidirectional muscle fibres, their deep fascia (including epimysium) and the articulation that they move in one direction on one plane. A new

functional classification is applied to body movements to facilitate analysis of motor variations. All movements are considered in terms of directions on spatial planes and are defined as follows: antemotion (AN), retromotion (RE), lateromotion (LA), mediomotion (ME), intrarotation (IR) and extrarotation (ER). Within each mf unit, in a precise location of the deep muscular fascia a specific point, termed centre of coordination (cc) is identified. Each cc is located in the point of convergence of the vectorial, muscular forces that act on a body segment during a precise movement. Biarticular muscles link unidirectional mf units to form mf sequences. One sequence is considered to monitor movement of several segments in one direction on the three planes. Sequences on the same spatial plane (sagittal, frontal, or horizontal) are reciprocal antagonists (i.e. AN is the antagonist of RE and vice versa) and are considered to be involved in the alignment of the trunk or limbs. Other points, termed centres of fusion (cf), located on the intermuscular septa, retinacula, and ligaments, monitor movements in intermediate directions between two planes and three-dimensional movements. The cf can interact either along mf diagonals or in mf spirals, according to the executed movement. Musculoskeletal dysfunction is considered to occur when muscular fascia no longer slides, stretches, and adapts correctly and fibrosis localises in these intersecting points of tension, known as cc and cf. Subsequent adaptive fibroses can develop as a consequence of unremitting non-physiological tension in a fascial segment.

Based on this functional classification, a systematic objective examination together with an analysis of three-dimensional movements of the implicated segments can pinpoint dysfunctional cc or cf. Comparative palpation then determines the selection of points requiring treatment in each individual case.

The manual technique itself consists in creating localised heat by friction by using the elbow, knuckle, or fingertips on the abovementioned points. The mechanical and chemical stress effects on connective tissue are well known and a local rise in temperature could affect the ground substance of the deep fascia in these specific points. Tensional adaptation can then propagate along an entire mf sequence, diagonal, or spiral, re-establishing a physiological balance. A fundamental element of this method lies in the fact that the myofascial sequence is not only a functional concept but has an anatomical substratum of fascial continuity and muscular expansions onto the fascia itself.

Methods and materials

Clinical study

Twenty-eight subjects with chronic posterior brachial pain (13 males and 15 females, mean age 62.7, Table 1) were treated by the same practitioner in an outpatient physiotherapy department, according to the methodology of Fascial Manipulation[®].

Informed consent for participation was obtained prior to treatments. Subjects who showed evidence of clinical neurological deficit, rotator cuff rupture, systemic inflammatory disease such as rheumatoid arthritis or had suffered direct trauma to the shoulder were excluded from the study. All subjects had had symptoms for more than 3 months. Prior to commencing treatment subjects were asked to evaluate the severity of their pain on a VAS scale from 1 to 10 [10 = worst possible pain, 0 = no pain]. This subjective evaluation was repeated after three treatment sessions and the sessions were then suspended. At a follow-up, 3 months after the end of treatments, a third measurement was recorded. The first two treatment sessions (Figure 2) were effectuated 1 week apart from each other and a third treatment 2 weeks later. The mean value of these measurements was then calculated and the analysis of the differences in pain was accomplished by comparing the results obtained with appropriate statistical tests (Kruskal–Wallis test and Dunn's multiple comparison test as a control).

Subjects were requested to abstain from any changes in usual medication.

Treatment procedure

A standardised procedure of anamnesis recorded age, occupation, sport activities, health history, symptoms, pain behaviour, and location. Any known painful movements, concomitant and previous pain, previous fractures, and surgical operations were also recorded. After the formulation of an initial hypothesis, specific movement tests aimed at testing the function of the mf units in selected body segments identified altered movements on all

Table 1 General characteristic of subjects.

Gender	Mean age	Number
Male	67	13
Female	58.8	15
Total	62.7	28

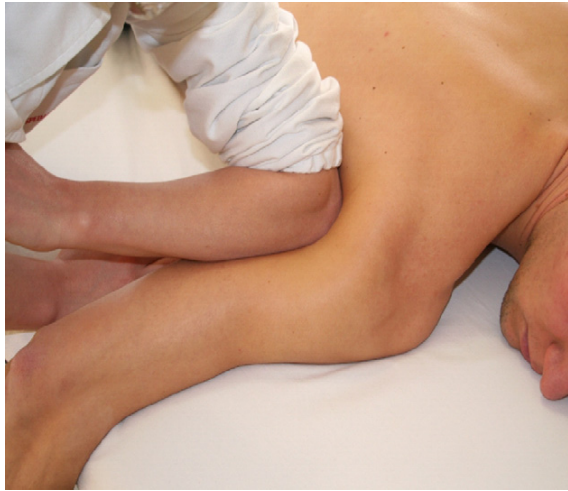

Figure 2 Photograph of treatment of a centre of coordination.

Table 2 Subjects examined.

Subject	Age	Gender
1	87	F
2	84	M
3	80	M
4	86	M
5	92	M
6	75	M
7	93	M
8	84	F
9	62	M
10	90	M
11	89	F
12	86	M
13	85	M
14	79	F
15	94	M
	Mean age 84.4	11 Male 4 Female

three spatial planes (sagittal, frontal and horizontal). Movement tests were evaluated according to Fascial Manipulation® protocol, on a scale from 1 to 3 asterisks: pain = *, weakness = * and limited movement = * (Table 2). The cc and/or cf of the most dysfunctional mf units (those with two or three asterisks) were then subjected to a comparative palpation assessment prior to selection of the points for treatment in each session. Following resolution of each cc or cf, the associated movement test was re-evaluated. A maximum of four fascial points were treated in each session. The cc and/or cf treated in each subject during each

treatment session had an individual combination that was chosen according to the results of the movement and palpation tests, together with other Fascial Manipulation® criteria for selecting points for treatment.

Anatomical study

In accordance with the choice to examine subjects with posterior upper limb pain, analysis of the posterior region of the arm was also performed via dissection of 15 cadavers (11 men, 4 women, mean age 84.4 years, Table 2), neither embalmed nor frozen previously. With the cadaver in the prone position, dissections consisted of an analysis of the posterior region of the shoulder and upper limb. Direct visual observations and photographs (Canon EOS 350 digital camera) were taken without magnification. After removing the skin and subcutaneous fat, the muscular fasciae and their structure were examined. Particular attention was paid to the direction of the collagen fibre bundles, the relationship of every muscle with its fascia, and the presence of any muscle fibres inserted directly into the overlying fascia. Similarly, the presence of any myofascial expansions (considered as fibrous extensions originating from the muscle and continuing beyond the muscle itself) into the brachial and antebrachial fascia were also noted, with particular attention to their spatial relationships.

All these expansions were photographed and subsequently catalogued.

Results

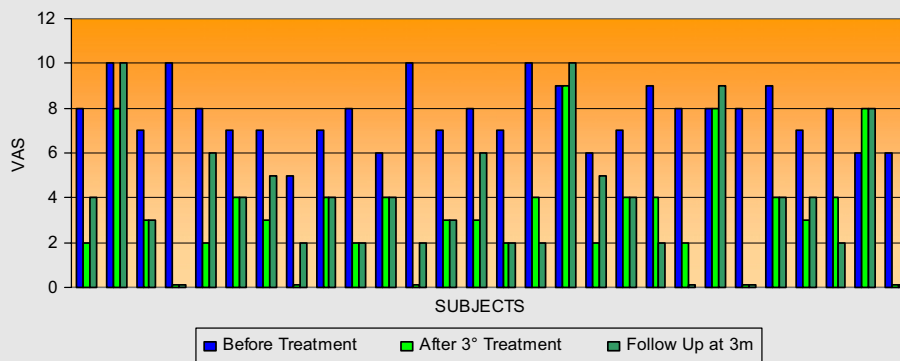
Clinical study

Pain distribution involved the scapular region and the triceps region in all subjects of the study group. Nine subjects also reported referred pain to the posterior region of the forearm. In seven subjects, distal paraesthesia, mostly to the fifth finger, was also reported. In all cases, a functional deficit in the range of shoulder movements was noted during movement tests. At the initial assessment, a majority of subjects (53%) presented a deficit in movement on the sagittal plane (Table 3). In one-third of cases, movement in the cervical region was also altered. No significant limitation in movement was noted in the elbow, even though in 30% of cases, pain extended to and below the elbow. In general, a dominance of sagittal plane limitations emerged from our analysis, and cc and/or cf along the anterior and/or posterior myofascial sequences (AN, RE) were treated in 15 subjects out of 28.

Table 3 Results of +ve movement tests on three planes in segments examined at the first visit in 28 subjects.

Body segments examined	Frontal plane						Sagittal plane						Horizontal plane					
	LA			ME			RE			AN			ER			IR		
	*	**	***	*	**	***	*	**	***	*	**	***	*	**	***	*	**	***
Scapula	3	3	1					2	1	2	1	2		1				1
Humerus	3	6	5		1		1	5	1	4	3	7	2	3	1	1	2	2
Elbow				1				1										1
Wrist							1	2										
Digits								2			1							
Neck	1	2					1	4	1	1	1		2	2	1			1
Thorax								3			1			2				
Lumbar		1						2	1		1		1					
Pelvis							1	2										
Hip	1							1										
Knee				1														
Total = 112	8	12	6	2	1		4	27	4	7	8	9	5	8	2	1	3	4

Table 4 Graph of subjective pain evaluation.



After the three treatments a mean pain reduction of 57% was recorded (mean value of VAS prior to treatment: 77 mm; mean value after three treatments: 32.8 mm) ($p < 0.0001$) together with a good recovery of movement. The initial benefit was generally maintained (mean value of VAS: 38.2 mm, $p > 0.05$) at a short-term follow-up. In eight cases, there was a partial increase in reported pain after the suspension of treatment, and in three cases, pain had returned to its initial level (Table 4).

Anatomical study

From our anatomical dissections, we have seen that the posterior region of the upper limb, in correspondence to the retromotion sequence from

Fascial Manipulation[®], has the following structure. Beginning at the hand, we have seen that the fascia of extensor digiti minimi and abductor digiti minimi is continuous with the deep muscular fascia of the posterior region of the forearm. Some of the fibres of abductor digiti minimi originate directly from the fascia, therefore, when these muscles contract they can transmit tension directly to the posterior antebrachial fascia. This fascia is tensioned distally also due to its insertions onto the flexor retinaculum, pisiform and pisohamate ligaments. The extensor carpi ulnaris extends a tendinous expansion onto the deep fascia of extensor digiti minimi and abductor digiti minimi (Figure 3). More proximally, some fibres of the proximal part of extensor carpi ulnaris and extensor digiti minimi originate from the antebrachial fascia. Fibrous

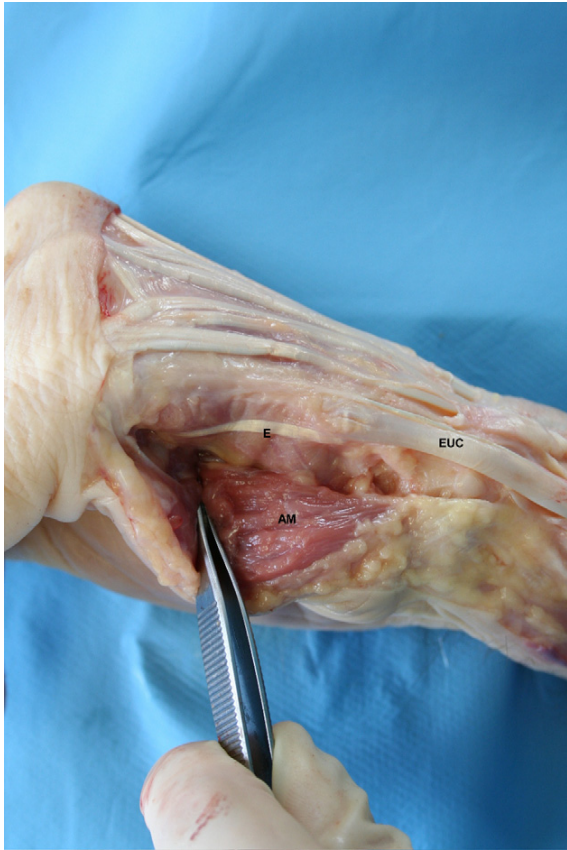


Figure 3 Hypothenar region: Continuity of extensor carpi ulnaris tendon with the deep fascia of extensor digiti minimi and abductor digiti minimi AM: abductor digiti minimi muscle, EUC: extensor carpi ulnaris, E: expansion.

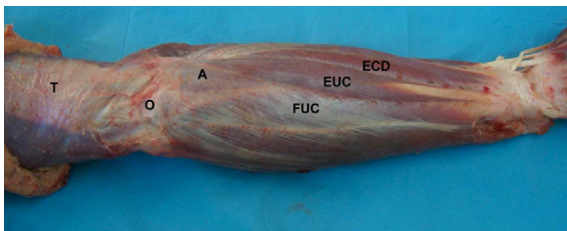


Figure 4 Posterior elbow and forearm region. EUC: extensor carpi ulnaris, ECD: extensor digitorum, A: anconeus, FUC: flexor carpi ulnaris, O: olecranon, and T: triceps.

septa originating from the internal surface of the posterior antebrachial fascia were also seen. These septa extend between extensor carpi ulnaris and anconeus on one side and extensor digiti minimi on the other side, giving origin to numerous fibres of the same muscles except anconeus, which does not appear to have insertions into its overlying fascia.

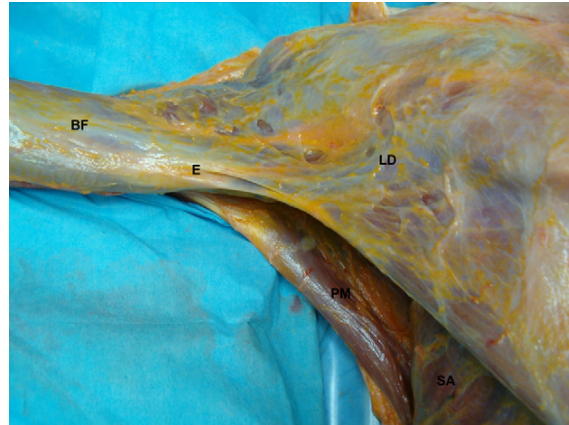

Figure 5 Posterior region of the upper arm. LD: latissimus dorsi muscle, BR: brachial fascia, and E: expansion.

In all dissections, we found that this same fascia also provides insertion for an important tendinous expansion of the triceps brachialis muscle, sometimes called the tricripital fascia. The triceps fibres that insert into the antebrachial fascia are all aligned in a longitudinal direction. They completely cover the anconeus muscle as well as the proximal insertion of the muscles that originate from the epicondyle. Hence, the posterior antebrachial fascia is subject to and can transmit tension both proximally and distally. Once the subcutaneous loose connective tissue was removed, the deep fascia of the forearm and elbow regions appeared as a sheer sheath covering the underlying muscles. Collagen fibres with different orientations were clearly visible (Figure 4). The antebrachial fascia is continuous with the brachial fascia.

In all dissections, the latissimus dorsi fascia proved to be continuous with the brachial fascia. Furthermore, latissimus dorsi sends a fibrous lamina to the triceps brachii fascia, creating a type of thickening in the posterior portion of the axillary fascia and, subsequently, in the brachial fascia (Figure 5). A fibrous arch extending from the triceps fascia to the tendon of latissimus dorsi further reinforces the connection between the two fasciae. The latissimus dorsi also inserts into the overlying fascia by means of numerous muscular fibres. Proximally, the posterior part of deltoid also tenses the brachial fascia over the triceps muscle. The deltoid muscle not only tenses the fascia, via the numerous septa that intersect it, but it also sends some muscular fibres to the aponeurosis that covers the muscles below the scapular spine. Medially, the deep fascia of posterior deltoid continues with that of trapezius and rhomboids.

Discussion

This study suggests that fascial anatomy can provide a biomechanical explanation for the effectiveness of myofascial treatments in musculoskeletal dysfunctions. It can serve as a guide for interpreting pain distribution but also as a topographical map for choosing specific, key areas for effective treatment. In particular, this pilot study has explored the possible effectiveness of applications of Fascial Manipulation[®] in an extremely common dysfunction such as chronic shoulder pain. A characteristic of this method is that it evaluates and treats points at a distance from the region where subjects experience their pain. The associated anatomical study has provided a clearer understanding of the validity of some of the anatomical bases of this method.

Our anatomical study demonstrates that myofascial continuity, provided by muscular insertions onto fascia, exists along the entire posterior upper limb. This continuity can offer a different perspective to the explanation of referred pain. In our study group, nine subjects had referral of pain from the posterior shoulder to the posterior forearm area, without clinical signs of neurological deficit. Their distribution of pain did not correspond to a precise nerve root, but it could be interpreted in terms of fascial connections along a limb. In particular, the anatomical study demonstrated that the muscular expansions into the fascia are present in all subjects and that they could stretch precise portions of fascia. We hypothesise that these muscular insertions allow the fascia to perceive stretch produced by a muscle and that this tension can be transmitted at a distance, both in a distal and a proximal direction. While the three-dimensional dispersion of forces within anatomical regions of the human body has yet to be thoroughly explored, studies of myofascial force transmission confirm that the actual stiffness of the general fascia and fascial compartments appear to be very important for the quantity of myofascial force transmission (Huijing and Baan, 2003). Both Paoletti (2002) and Stecco (2004) hypothesise that the deep fascia between two joints is directly involved in safeguarding a perceptive and directional continuity along a specific myokinetic chain or sequence. It could be that fascia acts somewhat like a sensitive transmission belt between two adjacent joints and synergic muscle groups. The precise stretching of selective regions of the fasciae due to these muscular expansions could activate receptors embedded in the fasciae (Barker, 1974; Stecco et al., 2006).

Transformation of the extracellular matrix of the deep fascia from sol to gel, for example, due to

over-use syndromes, strain, and repetitive stress injuries would modify the capacity of the endofascial collagen fibres to slide over one another causing a change in stiffness. This could produce two effects: firstly, a mechanical or tensional reaction and secondly, a possible alteration in afferent signals. In the first case, in an attempt to compensate for localised changes in viscosity, tension could extend along a mf sequence, or myokinetic chain, either in an ascending or descending manner, or else, between agonist and antagonist myofascial sequences on one spatial plane. This could possibly be the explanation for the dominance of the sagittal plane involvement (53%) together with the posterior brachial pain distribution found in our study group. In fact, patients with referred myofascial pain that does not correspond to a specific nerve root distribution are common in clinical practice (Baldry, 2001). Furthermore, seven subjects of our study reported distal paraesthesia mostly involving the fifth finger, which is the distal end of the retromotion sequence, as reported above. According to Fascial Manipulation[®] theory (Stecco, 2004), distal paraesthesia may occur when the fascia is not free to glide and subsequent fascial tension along a sequence culminates in the terminal part of a sequence. Stecco (2004) also suggests that this mechanism implies a basal or resting tension of the fascia. The documented insertions of muscle fibres onto overlying fascia could contribute decisively to the maintenance of a basal tension (Stecco et al., 2007). Recent studies providing evidence of myofibroblasts within the fascia (Schleip et al., 2006) suggest another component that may contribute to a basal fascial tension or fascial contractility.

An understanding of the anatomical continuity of the deep fascia supports this paradigm shift as it helps to explain how alterations in one body segment can result in changes in a distant segment. Like trigger points, an alteration of a cc, for example in the deep fascia of the triceps muscle, can result in referred pain in both a distal and a proximal direction. Considering the above myofascial expansions, fascial continuity could be responsible for the referral of pain along a sequence, even in the absence of nerve root disturbance. In the presence of non-neurological referred pain in some patients from the study group, manual treatment of a proximal cc over the deep fascia together with a distal point produced interesting results in terms of pain reduction and restored movement. Clinically, this indicates that work along an entire myofascial chain in order to alleviate extended myofascial pain may not be necessary.

Concerning alterations in afferent signals, any incorrect activation of receptors embedded in the impeded fascia could result in inaccurate proprioceptive afferents. Consequent incoherent muscle recruitment would produce repercussions on joint movement (e.g. impingement) and poorly coordinated joint movement can cause periarticular inflammation, resulting in activation of nociceptors around the joint.

The biomechanical model proposed by the Fascial Manipulation[®] technique offers interesting possibilities for more in-depth studies.

Conclusion

In conclusion, this study suggests that fascial anatomy can provide a biomechanical explanation for the effectiveness of myofascial treatments in musculoskeletal dysfunctions. Fascial anatomy can also serve as a guide to interpreting pain distribution and a topographical map for identifying specific, key areas for effective treatment.

References

- Baldry, P., 2001. Myofascial Pain and Fibromyalgia Syndromes. Churchill Livingstone, New York, NY.
- Barker, D., 1974. The morphology of muscle receptors. In: Hunt, C.C. (Ed.), Handbook of Sensory Physiology. Springer, Berlin, pp. 1–190.
- Birnbaum, K., Siebert, C.H., Pandorf, T., Schopphoff, E., Prescher, A., Niethard, F.U., 2004. Anatomical and biomechanical investigations of the iliotibial tract. *Surgical and Radiologic Anatomy* 26, 433–446.
- Busquet, L., 1995. Les chaines musculaires. Tome II. Frison Roche, Paris.
- Fairclough, J., Hayashi, K., Toumi, H., Lyons, K., Bydder, G., Phillips, N., Best, T.M., Benjamin, M., 2006. The functional anatomy of the iliotibial band during flexion and extension of the knee: implications for understanding iliotibial band syndrome. *Journal of Anatomy* 208, 309–316.
- Godelieve, Denys-S., 1996. Il manuale del Méziérista vols. I and II. Marrapese, Roma.
- Gracovetsky, S., Farfan, H., Helleur, C., 1985. The abdominal mechanism. *Spine* 10, 317–324.
- Green, S., Buchbinder, R., Hetrick, S., 2003. Physiotherapy interventions for shoulder pain. *Cochrane Database Systematic Reviews*, CD004258.
- Huijing, P., Baan, G., 2003. Myofascial force transmission: muscle relative position and length determine agonist and synergist muscle force. *Journal of Applied Physiology* 94, 1092–1107.
- Kitaoka, H.B., Luo, Z.P., An, K.N., 1997. Mechanical behavior of the foot and ankle after plantar fascia release in the unstable foot. *Foot & Ankle International* 18, 8–15.
- Langevin, H., 2006. Connective tissue: a body-wide signalling network? *Medical Hypotheses* 66, 1074–1077.
- Loukas, M., Shoja, M.M., Thurston, T., Jones, V.L., Linganna, S., Tubbs, R.S., 2007. Anatomy and biomechanics of the vertebral aponeurosis part of the posterior layer of the thoracolumbar fascia. *Surgical and Radiologic Anatomy* 30, 125–129.
- Myers, T.W., 2001. *Anatomy Trains*. Churchill Livingstone, New York, NY.
- Paoletti, S., 2002. Les Fascias: Role des Tissus dans la Mécanique Humaine. Vannes, Sully.
- Picavet, H.S.J., Schouten, J.S.A.G., 2003. Musculoskeletal pain in the Netherlands: prevalences, consequences and risk groups, the DMC (3)-study. *Pain* 102, 167–178.
- Rolf, I.P., 1997. *Rolfing*. Mediterranee, Roma.
- Schleip, R., Lehmann-Horn, F., Klingler, W., 2006. Fascia is able to contract in a smooth muscle-like manner and thereby influence musculoskeletal mechanics. In: Liepsch, D. (Ed.), Proceedings of the Fifth World Congress of Biomechanics, Munich, Germany, 2006, pp. 51–54, ISBN 88-7587-270-8.
- Stecco, L., 2004. Fascial Manipulation. Piccin, Padova.
- Stecco, C., Porzionato, A., Macchi, V., Tiengo, C., Parenti III, A., Aldegheri, R., Delma, V., De Caro, R., 2006. A histological study of the deep fascia of the upper limb. *Italian Journal of Anatomy and Embryology* 111 (2), 105–110.
- Stecco, C., Gagey, O., Macchi, V., Porzionato, A., De Caro, R., Aldighieri, R., Delmas, V., 2007. Tendinous muscular insertions onto the deep fascia of the upper limb. First part: anatomical study. *Morphologie* 91 (292), 29–37 http://www.ncbi.nlm.nih.gov/sites/entrez?Db=pubmed&Cmd=Search&Term=%22GageyO%22%5BAuthor%5D&itool=EntrezSystem2.PEntrez.Pubmed.Pubmed_ResultsPanel.Pubmed_RVAbstractPlusDrugs1.
- Vleeming, A., Stoeckart, R., Snijders, C.J., 1995. The posterior layer of the thoracolumbar fascia. *Spine* 20, 753–758.
- Yahia, H., Rhalmi, S., Newman, N., 1992. Sensory innervation of human thoracolumbar fascia, an immunohistochemical study. *Acta Orthopaedica Scandinavica* 63, 195–197.
- Yu, J.S., 2000. Pathologic and post-operative conditions of the plantar fascia: review of MR imaging appearances. *Skeletal Radiology* 29, 491–501.