

LITERATURE REVIEW

A Systematic Review of the Soft-Tissue Connections Between Neck Muscles and Dura Mater

The Myodural Bridge

Luis Palomeque-del-Cerro, PT, PhD,^{*,†,‡} Luis A. Arráez-Aybar, MD, PhD,[§] Cleofás Rodríguez-Blanco, PT, PhD,[¶] Rafael Guzmán-García, PT,[‡] Mar Menendez-Aparicio, PT,^{||} and Ángel Oliva-Pascual-Vaca, PT, PhD[¶]

Study Design. Systematic review.

Objective. To elucidate the existence of soft tissue connections between the neck muscles and cervical dura mater.

Summary of Background Data. Several studies discuss the existence of a cervical myodural bridge; however, conflicting data have been reported.

Methods. Searches were conducted in the PubMed, Web of Science, Cochrane Library, and PEDro databases. Studies reporting original data regarding the continuity of non-post-surgical soft tissue between the cervical muscles and dura mater were reviewed. Two reviewers independently selected articles, and a third one resolved disagreements. Another two researchers extracted the methodology of the study, the anatomical findings, and evaluated the quality of the studies using Quality Appraisal for Cadaveric Studies Scale. A different third researcher resolved disagreements.

Results. Twenty-six studies were included. A soft tissue connection between the rectus capitis posterior minor, the rectus capitis posterior major, and the obliquus capitis inferior muscles seems to be proved with a strong level of evidence for each one of them. Controversy exists about the possible communication

between the dura mater and the upper trapezius, rhomboideus minor, serratus posterior superior, and splenius capitis by means of the ligamentum nuchae. Finally, there is limited evidence about the existence of a soft tissue connection between rectus capitis anterior muscle and the dura mater.

Conclusion. There is a continuity of soft tissue between the cervical musculature and the cervical dura mater; this might have physiological, pathophysiological, and therapeutic implications, and going some way to explaining the effect of some therapies in craniocervical disorders.

Key words: anatomy, cerebrospinal fluid, connective tissue, dura mater, fascia, muscles, neck muscles, proprioception, spine, superficial back muscles.

Level of Evidence: N/A

Spine 2017;42:49–54

From the ^{*}Department of Physical Therapy, Occupational Therapy, Rehabilitation and Physical Medicine, Universidad Rey Juan Carlos, Alcorcón, Madrid, Spain; [†]Faculty of Nursery and Physical Therapy “Salus Infirmorum”, Universidad Pontificia de Salamanca, Madrid, Spain; [‡]Madrid Osteopathic School, Madrid, Spain; [§]Department of Human Anatomy and Embriology, Complutense University of Madrid, Madrid, Spain; [¶]Department of Physiotherapy, University of Sevilla, Seville, Spain; and ^{||}Ofistema, Madrid, Spain.

Acknowledgment date: February 14, 2016. First revision date: March 23, 2016. Acceptance date: April 7, 2016.

The manuscript submitted does not contain information about medical device(s)/drug(s).

No funds were received in support of this work.

No relevant financial activities outside the submitted work.

Address correspondence and reprint requests to Ángel Oliva-Pascual-Vaca, PT, PhD, Department of Physiotherapy, Faculty of Nursery, Physiotherapy and Podiatry, University of Sevilla, C/Avicena s/n, 41009 Sevilla, Spain; E-mail: angeloliva@us.es

DOI: 10.1097/BRS.0000000000001655

Craniocervical pain has a high prevalence with considerable physical, psychological, and socioeconomic effects^{1,2}; however, the pathophysiology of many of the disorders involving craniocervical pain are still not completely understood.³ These disorders may relate to issues as seemingly disparate as posture and muscle condition⁴ or the state of the cerebrospinal fluid,⁵ making the diagnosis of a patient with craniocervical pain a real challenge.

For the treatment of these pathologies, the suboccipital region has been commonly the target area of different approaches^{6–9} based on its anatomy, which has been studied in depth recently. It has been described the existence of a myodural bridge, which means a connection between dura mater and muscles by means of soft tissue. According to this structure, several changes to the classical anatomy have been claimed, such as the inclusion of the rectus capitis posterior minor (RCPmi) myodural bridge in the anatomy textbooks,¹⁰ but some findings seem to be contradictory, such as the existence or not of a connection between cervical muscles and the dura mater by means of ligamentum nuchae (LN).^{11,12} Besides, as a result of these new craniocervical

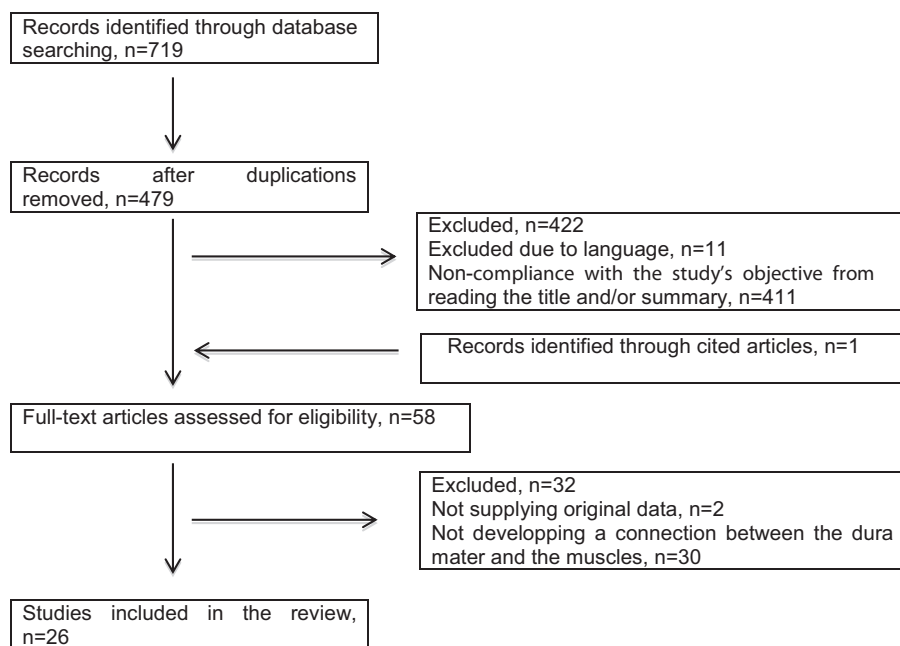


Figure 1. Flowchart diagram.

anatomic knowledge regarding the existence of a fascial continuity between the cervical muscles and the dura mater, several physiological,¹³ pathophysiological,¹⁴ diagnostic,¹⁵ and therapeutic⁸ consequences have been proposed related to craniocervical disorders.

The aim of the present study is to systematically review the recent anatomical findings regarding the existence of a soft tissue bridge between the cervical muscles and the dura mater in the upper cervical spine.

METHODS

This systematic review has been performed according to the Preferred Reporting Item for Systematic Reviews and Meta-Analyses (PRISMA) guidelines.¹⁶

Search Strategy

A systematic search of PubMed, Web of Knowledge, the Cochrane Library, and PEDro was performed between 29 and 31 November 2015 with no limits on dates. In the first three databases the specific search string used was *([ligament* OR musc*] AND [cervic* OR neck] AND ["dura mater" OR mening*]) OR "myodural bridge."* In the PEDro database, the search terms were *myodural*, *"dura mater,"* *dura* and *duramater*. We also reviewed "cited-by" articles to ensure that every suitable study was included.

Study Selection

We included in this review any article published in scientific journals in English, Spanish, Portuguese, or French which report original data of a continuity of non-post-surgical soft tissues between the cervical muscles and the dura mater. Studies were excluded if the continuity described between the cervical musculature and the dura mater was achieved through intermediate bony elements. The study selection

was undertaken independently by two members of the research team (M.M. and A.O.) according to the inclusion and exclusion criteria. If needed, a third member of the research team (C.R.) resolved any disagreements. Figure 1 shows the flow diagram for the selection process.

Data Extraction

Once the studies had been selected the following information was retrieved from each one: bibliographic reference, participating sample, methodology followed to allow a description of the soft tissue that formed a continuity between muscle tissue and the dura mater, and the anatomical findings. These data were obtained by two researchers (R.G. and L.P.) following a standardized form. Disagreements were resolved by a third researcher (L.A.).

Methodological Quality

QUACS Scale (Quality Appraisal of Cadaveric Studies), which is a highly reliable scale in assessing the methodological quality of observational dissection studies,^{17,18} was used to evaluate the methodological quality of the selected studies. This scale is conformed by a checklist of 13 dichotomous items, which can be pointed with zero (no/not stated) or one (yes/clearly present). Percentage is used to score the quality of the study. Eighty-one percent to 100% indicate excellent, 61% to 80% substantial, 41% to 60% moderate, 21% to 40% fair, and 0% to 20% poor methodological quality. These ratings were done by the same two researchers who performed data extraction, and disagreements were also resolved by the third one. Finally, according to the Cochrane Collaboration Back Review Group,¹⁹ the level of evidence was considered not existent (no studies available), conflicting (inconsistent findings among multiple studies), limited (one low-quality study), moderate (consistent

TABLE 1. Methodology and Anatomical Findings in the Selected Studies

Study	Sample Size	Sample Type	Method	MB (Interspace)
1. Lazorthes <i>et al</i> , 1953 ²⁰	25	ND	ND	RCPmi (Occ-C1)
2. Kahn <i>et al</i> , 1992 ²¹	8	Adult–New born	Diss–Hist–MRI–scanography	RCPmi (Occ-C1); RCPma (C1-C2) OCI (C1-C2)
3. Hack <i>et al</i> , 1995 ¹³	11	Adult	Diss (emb–fresh)	RCPmi (Occ-C1)
4. Hack <i>et al</i> , 1996 ²²	ND	Cadaver–clinical population	MRI (T1 and T2)	RCPmi (Occ-C1); Not defined muscle (C1-C2)
5. Rutten <i>et al</i> , 1997 ²³	7	ND	Diss (emb–fresh)	RCPmi (Occ-C1) LN (Occ-C1 and C1-C2)
6. Hack <i>et al</i> , 1997 ²⁴	1	ND	Diss (emb)	Suboccipital muscles (C1-C2)
7. Mitchell <i>et al</i> , 1998 ²⁵	10	Adult	Diss (emb)	LN (C1-C2) RCPmi
8. Koritzer and Harris, 2000 ²⁶	>30	Cadaver	Diss–Hist	RCA
9. Johnson <i>et al</i> , 2000 ²⁷	8	Adult	Diss–Plast (E12)	No LN
10. Dean and Mitchell, 2002 ²⁸	10	Adult	Diss	LN (Occ-C1 and C1-C2) RCPmi
11. Zhang and Lee, 2002 ²⁹	6	Adult	Plast (E12)	No LN (Occ-C1 nor C1-C2)
12. Humphreys <i>et al</i> , 2003 ³⁰	30	Cadaver	Diss (emb)–MRI	LN (C1-C2) RCPmi (Occ-C1)
13. Hack and Hallgren, 2004 ⁸	1	Clinical population	MRI–surgery	RCPmi (Occ-C1)
14. Nash <i>et al</i> , 2005 ¹¹	22	Adult	Diss (emb)–Plast (E12)	RCPmi No LN (Occ-C1)
15. Zumpano <i>et al</i> , 2006 ³¹	75	ND	Diss	RCPmi
16. Demetrious, 2007 ³²	1	Living adult	MRI	RCPmi
17. Scali <i>et al</i> , 2011 ³³	13	Adult	Diss (emb)	RCPmi RCPma (C1-C2) OCI (C1-C2) No OCS
18. Kahkeshani and Ward, 2012 ¹⁰	1	ND	Diss	RCPmi
19. Scali <i>et al</i> , 2013 ³⁴	11	ND	Diss (emb–fresh)	RCPma (C1-C2) OCI (C1-C2)
20. Scali <i>et al</i> , 2013 ¹⁵	240	Clinical population	MRI	RCPmi (Occ-C1); RCPma (C1-C2) OCI (C1-C2)
21. Pontell <i>et al</i> , 2013 ³⁵	9	ND	Diss	RCPmi RCPma OCI (C1-C2)
22. Pontell <i>et al</i> , 2013 ¹⁴	8	Adult	Diss (emb)–Hist (neuroanalysis)	RCPma OCI
23. Pimenta <i>et al</i> , 2014 ³⁶	11	Adult–fetus	Diss (fresh)–Hist	RCPmi (Occ-C1); RCPma (C1-C2) No LN (Occ-C1 nor C1-C2)
24. Zheng <i>et al</i> , 2014 ¹²	30	Adult	Diss–Plast (P45)	LN (C1-C2)
25. Yuan <i>et al</i> , 2015 ³⁷	19	Adult	Diss–Plast (P45) (emb)	RCPmi (Occ-C1) (C1-C2)
26. Scali <i>et al</i> , 2015 ³⁸	23	Adult	Diss–Plast (E12)–Hist–Emb	RCPmi (Occ-C1); RCPma (C1-C2) OCI (C1-C2)

C1 indicates atlas; C2, axis; Diss, dissection; Dura, dura mater; Hist, histological analysis; ND, not defined; LN, ligamentum nuchae; MB, myodural bridge; MRI, magnetic resonance imaging; Occ, occipital bone; OCI, obliquus capitis inferior; OCS, obliquus capitis superior; Plast, plastination; RCA, rectus capitis anterior; RCPma, rectus capitis posterior major; RCPmi, rectus capitis posterior minor.

findings among multiple low-quality studies or one high-quality study), or strong (consistent findings among multiple high-quality studies).

RESULTS

From the systematic literature search, 479 studies were identified. Taking into account the exclusion criteria and

the study's objectives from reading the title and/or the summary, 422 studies were excluded. One more record was included from the reference list of an article. After full-text reading, 26 studies were finally included in this review (Figure 1). Twenty of the selected articles correspond to observational studies, with the original observational data from one of them included within a review article.

Two selected articles were anatomical findings described in case study reports, whereas another three articles included in the review were letters that contained original observational data. Lastly, one of the articles selected related to original observational data included in a summary of a communication at a conference.

The majority of the studies approached the subject through dissections, mainly of embalmed corpses, although there were also studies of fresh cadavers. The techniques of plastination were used in five investigations. Magnetic resonance imaging of cadavers was performed in two studies, whereas in five investigations magnetic resonance imaging was performed on live subjects. Histological analysis was performed on tissue samples in six of the studies. Lastly, one other study used CAT scans, whereas in another the confirmation of the existence of the myodural bridge came from a surgical procedure (Table 1).

Myodural bridges were found at the level of the occiput-C1 and C1–C2 intervals, but with various degrees of evidence to support their existence. There is strong evidence about the existence of a soft tissue continuity between the dura mater and three suboccipital muscles: RCPmi, rectus capitis posterior major (RCPma) and obliquus capitis inferior (OCI). On the contrary, there is conflicting evidence about the existence of a continuity between the dura mater and the LN, in which several muscles such as upper trapezius (UT), splenius capitis (SC), rhomboideus minor (RM), and serratus posterior superior (SPS) are attached. To finish with, evidence about a bridge between the rectus capitis anterior (RCA) is limited (Table 2).

DISCUSSION

The present systematic review provides important information for professionals managing with people suffering from several craniocervical disorders because direct morphological continuity between cervical muscles and the dura mater constitutes the empirical background to extend diagnostic and therapeutic focus beyond one single anatomical structure separately.¹⁸ The results of this review confirm the existence of myofascial bridges with the dura mater at a cervical level in relation to the RCPmi, RCPma,

and OCI muscles. With respect to the RCA, despite only one study²⁶ mentions the anterior myodural bridge, it confirmed its existence in more than 30 cadavers dissected and subsequent histological analysis. More research is, however, needed to confirm the existence of this bridge. Finally, regarding possible connection between the UT, SC, RM, and SPS muscles with the dura mater through the LN, it seems controversial. While several studies affirm the existence of this bridge (five studies that analyzed a total of 87 cases) a similar number of studies deny its existence (four studies) although they only studied about half as many cases (47 cases). A possible explanation for this disagreement can be the fact that, despite some authors have described the bridge between the LN and the dura mater to be a dense fibrous band,²⁹ other authors have described the upper part of the LN to be constituted by loose fatty connective tissue so that they discard it as a connective junction, considering it a fatty space.²⁷ It must be taken into account that it is not always easy to clearly identify the limit between two kinds of tissue and the fact that there is no absolute criterion to determine what “loose” means.²⁹ Anyway, other authors consider that even being thin loose connective tissue, it might have a potential functional importance.¹¹

An historical perspective can be helpful to understand the results obtained in this systematic review. The first reference encountered is that of Lazorthes *et al*²⁰ from 1953, who only described the myodural bridge of the RCPmi. This article was published in French, which could have limited its audience. Up until 1992 there were no other descriptions of dural unions in the RCPma and OCI.²¹ Hack *et al*¹³ in 1995 affirm that they were the first to describe a myodural bridge, specifically with the RCPmi. Their publication in English and the consolidation of the bibliographic databases in these dates has meant that they are considered to be the first authors to discover the existence of a myodural bridge and this may be the reason why there are many more studies focusing on the RCPmi. The research into the bridges of the RCPma and OCI muscles intensified from 2011.³³ It is also interesting that the study by Koritzer and Harris²⁶ regarding the presence of an anterior myodural bridge with the RCA has never been cited in the data available through the Web of

TABLE 2. Number and Quality of Included Studies Reporting Soft Tissue Continuity Between Cervical Muscles and the Dura Mater: Level of Evidence

	Total	Excellent	Substantial	Moderate	Fair	Poor	Level of Evidence
RCPmi	19	1	9	6	2	1	Strong
RCPma	8	2	5	1			Strong
OCI	7	2	4	1			Strong
LN	5		2	2	1		Conflicting
No LN	4		3	1			
RCA	1				1		Limited

LN indicates ligamentum nuchae; No LN, ligamentum nuchae does not bridge to dura mater; OCI, obliquus capitis inferior; RCA, rectus capitis anterior; RCPma: rectus capitis posterior major; RCPmi: rectus capitis posterior minor.

Science. In addition, this study is only recorded in this database and it relates to a summary of a communication at a conference, which may go some way to suggesting why there has not been more research into this anterior myofascial bridge.

The fact that all of the investigations found the bridges in every studied specimen or in a very high percentage of them implies that these results are not incidental findings or anatomic abnormalities. In this sense, the various authors that have addressed the issue have suggested that these myodural connections may have a functional meaning, and pathophysiological and therapeutic implications. Despite they seem to be important, none of them has, however, been probed, so more research is needed to elucidate them.

LIMITATIONS

QUACS Scale was designed to assess observational cadaveric studies, whose aim is mostly to get anatomical data. In this review, five of the studies were performed on living subjects as a sample. They were observational anatomical studies and case reports in which the authors described observational anatomical data. To our knowledge there are no suitable scales to assess the methodological quality of these types of study; however, we found no problem when using QUACS Scale in these articles, because all of the items included in the QUACS Scale could be easily applied on these five investigations. Furthermore, some of the articles reviewed had low quality. In them, the methodology used for obtaining the reported original anatomical data has not been fully explained as the studies were very old or from scientific letters or in a summary of a communication at a conference.

In conclusion, the present review provides first systematic evidence of the existence of a morphofunctional soft tissue continuity between the neck muscles and cervical dura mater. The existence of these myodural bridges has been demonstrated for RCPmi, RCPma, and OCI muscles, but not for RCA, RM, SC, UT, or SPS muscles. Clinicians may consider the myodural bridge as a structural demonstrated element but should be aware that more research is needed about its meaning and possible pathophysiological and therapeutic implications.

➤ Key Points

- ❑ This systematic review provides evidence of the existence of physiological soft tissue connections between dura mater and RCPmi, RCPma, and OCI muscles.
- ❑ Controversy exists about the possible communication between the dura mater and the UT, RM, SPS, and SC by means of the LN.
- ❑ There is limited evidence about the existence of a soft tissue connection between RCA muscle and the dura mater.

- ❑ The myodural bridge may have a physiological role.
- ❑ It also might help to explain certain symptoms on subjects suffering from craniocervical disorders, and the mechanical and neurophysiological effects of physical interventions such as massage, exercise, manipulation, or surgical section.

References

1. Ayzenberg I, Katsarava Z, Sborowski A, et al. The prevalence of primary headache disorders in Russia: a countrywide survey. *Cephalalgia* 2012;32:373–81.
2. Cohen SP. Epidemiology, diagnosis and treatment of neck pain. *Mayo Clinic Proc* 2015;90:284–99.
3. Sheikh HU. Approach to chronic daily headache. *Curr Neurol Neurosci Rep* 2015;15:4.
4. De-las-Peñas C, Alonso-Blanco C, Cuadrado ML, et al. Trigger point in the suboccipital muscles and forward head posture in tension-type headache. *Headache* 2006;46:454–60.
5. Hebert-Blouin MN, Mokri B, Shin AY. Cerebrospinal fluid volume-depletion headaches in patients with traumatic brachial plexus injury. Clinical article. *J Neurosurg* 2013;118:149–54.
6. Antolinos-Campillo PJ, Oliva-Pascual-Vaca A, Rodríguez-Blanco C, et al. Short-term changes in median nerve neural tension after a suboccipital inhibition technique in subjects with cervical whiplash: a randomised controlled trial. *Physiotherapy* 2014;100:249–55.
7. Espi-López GV, Rodríguez-Blanco C, Oliva-Pascual-Vaca A, et al. Effect of manual therapy techniques on headache disability in patients with tension-type headache. Randomized controlled trial. *Eur J Phys Rehabil Med* 2014;50:641–7.
8. Hack GD, Hallgren RC. Chronic headache relief after section of suboccipital muscle dural connections: a case report. *Headache* 2004;44:84–9.
9. Heredia Rizo AM, Oliva Pascual-Vaca A, Albornoz Cabello M, et al. Immediate effects of the suboccipital muscle inhibition technique in craniocervical posture and greater occipital nerve mechanosensitivity in subjects with a history of orthodontia use: a randomized trial. *J Manipulative Physiol Ther* 2012;35:446–53.
10. Kahkeshani K, Ward PJ. Connection between the spinal dura mater and suboccipital musculature: evidence for the myodural bridge and a route for its dissection—a review. *Clin Anat* 2012;25:415–22.
11. Nash L, Nicholson H, Lee AS, et al. Configuration of the connective tissue in the posterior atlanto-occipital interspace: a sheet plastination and confocal microscopy study. *Spine* 2005;30:1359–66.
12. Zheng N, Xiao-Ying Y, Li YF, et al. Definition of the to be named ligament and vertebral ligament and their possible effects on the circulation of CSF. *PLOS One* 2014;9:e103451.
13. Hack GD, Koritzer RT, Robinson WL, et al. Anatomic relation between the rectus capitis posterior minor muscle and the dura mater. *Spine* 1995;20:2484–6.
14. Pontell ME, Scali F, Enix DE, et al. Histological examination of the human obliquus capitis inferior myodural bridge. *Ann Anat* 2013;195:522–6.
15. Scali F, Pontell ME, Welk AB, et al. Magnetic resonance imaging investigation of the atlanto-axial interspace. *Clin Anat* 2013;26:444–9.
16. Moher D, Liberati A, Tetzlaff J, et al. Preferred reporting items for systematic reviews and meta-analyses: the PRISMA statement. *PLoS Med* 2009;6:e1000097.
17. Wilke J, Krause D, Niederer T, et al. Appraising the methodological quality of cadaveric studies: validation of the QUACS Scale. *J Anat* 2015;226:440–6.

18. Wilke J, Krause F, Vogt L, et al. What is evidence-based about myofascial chains: a systematic review. *Arch Phys Med Rehabil* 2016;97:454–61.
19. Van Tulder M, Malmivaara A, Chou R, et al. 2015 Updated method guideline for systematic reviews in the Cochrane collaboration back and neck group. *Spine* 2015;40:1660–73.
20. Lazorthes G, Poulhes J, Gaubert J. La duremere de la charniere cranio-rachidienne. *Bull Assoc Anat* 1953;78:169–72.
21. Kahn JL, Sick H, Koritké JG. The posterior intervertebral spaces of the caniovertebral joint. *Acta Anat* 1992;144:65–70.
22. Hack GD, Rothman M, Schwartz AH, et al. Letters. *Spine* 1996;21:2300–1.
23. Rutten HP, Szpak K, Van Mameren H, et al. Letters. *Spine* 1997;22:924–5.
24. Hack GD, Koritzer RT, Robinson WL. Letters. *Spine* 1997;22:925–6.
25. Mitchell BS, Humphreys BK, O'Sullivan E. Attachments of the ligamentum nuchae to cervical posterior spinal dura and the lateral part of the occipital bone. *J Manipulative Physiol Ther* 1998;21:145–8.
26. Koritzer RT, Harris RR. Anterior myodural bridge in the cranio-spinal space: a reciprocal relation with the posterior myodural bridge. *Am J Phys Anthropol* (suppl 30):2000;200.
27. Johnson GM, Zhang M, Jones DG. The fine connective tissue architecture of the human ligamentum nuchae. *Spine* 2000;25:5–9.
28. Dean NA, Mitchell BS. Anatomic relation between the nuchal ligament (ligamentum nuchae) and the spinal dura mater in the craniocervical region. *Clin Anat* 2002;15:182–5.
29. Zhang M, Lee ASJ. The investing layer of the deep cervical fascia does not exist between the sternocleidomastoid and trapezius muscles. *Otolaryngol Head Neck Surg* 2002;127:452–7.
30. Humphreys BK, Kenin S, Hubbard BB, et al. Investigation of connective tissue attachments to the cervical spinal dura mater. *Clin Anat* 2003;16:152–9.
31. Zumpano MP, Hartwell S, Jagos CS. Soft tissue connection between rectus capitis posterior minor and the posterior atlantooccipital membrane: a cadaveric study. *Clin Anat* 2006;19:522–7.
32. Demetrious J. Post-traumatic upper cervical subluxation visualized by MRI: a case report. *Chirop Osteopat* 2007;15:20.
33. Scali F, Marsili ES, Pontell ME. Anatomical connection between the rectus capitis posterior major and the dura mater. *Spine* 2011;36:E1612–4.
34. Scali F, Pontell ME, Enix DE. Histological analysis of the rectus capitis posterior major's myodural bridge. *Spine J* 2013;13:558–63.
35. Pontell ME, Scali F, Marshall E, et al. The obliquus capitis inferior myodural bridge. *Clin Anat* 2013;26:450–4.
36. Pimenta NJ, Gusmão SS, Kehrl P. Posterior atlanto-occipital and atlanto-axial area and its surgical interest. *Arq Neuropsiquiatr* 2014;72:788–92.
37. Yuan XY, Yu SB, Li YF, et al. Patterns of attachment of the myodural bridge by the rectus capitis posterior minor muscle. *Anat Sci Int* 2016;91:175–9.
38. Scali F, Pontell ME, Nash LG, et al. Investigation of meningo-myovertebral structures within the upper cervical epidural space: a sheet plastination study with clinical implications. *Spine J* 2015;15:2417–24.