

ORIGINAL COMMUNICATION

A History of Fascia

SUE ADSTRUM^{1*} AND HELEN NICHOLSON²¹Independent Anatomy Researcher, Auckland, New Zealand²Department of Anatomy, School of Biomedical Sciences, University of Otago, Dunedin, New Zealand

Fascia is a generic anatomical term that refers to a variety of the body's soft fibrous connective tissue parts. An expanding interdisciplinary interest in fascia might be accompanied by changes in how fascia is cognized. This study surveys the anatomical portrayal of fascia through history, with the aim of helping contextualize the ways it is now known. A historiographic review of fascia-related literature written in the English language was undertaken. The anatomical meaning associated with fascia has varied during the 400 years that this term has been incorporated in English-language medical literature. Fascia has been diversely portrayed as a range of macroscopically discernable body parts, the tissues they are composed of, and a pervasive soft connective tissue network structure. Over the last four centuries, fascia has been described in many ways. Anatomical understanding of fascia has developed over the years and is likely to continue to change with evolving research technologies. Multidisciplinary advances in fascial knowledge could conceivably contribute to improving individual and societal health care. Clin. Anat. 32:862–870, 2019. © 2019 Wiley Periodicals, Inc.

Key words: anatomical terminology; fascia; fascial system; integrative anatomy; medical history

INTRODUCTION

Fascia is thought to be a Latinized version of the ancient Greek word *taenia*, which was applied to a variety of thin, strip-like objects, including bandages and ribbons (Hooper, 1797; Liddell et al., 2011).¹ In Roman times, the feminine Latin noun *fascia* and its plural *fasciae* were similarly construed (Lewis and Short, 1966; Glare, 1982), yet it is unclear whether the Romans or Greeks imbued this word with anatomical meaning. Since its 16th century importation into the English language, this word has been applied to an expanding range of objects that manifest a band or fillet-like appearance (Simpson and Weiner, 1989). Examples include the long, flat surfaces on the outside of buildings (including fascia boards and advertising nameplates), well-defined bands of color on birds, and the removable front face of a mobile phone. Nowadays, anatomists generically relate this term to

"sheaths, sheets or other dissectible masses of connective tissue that are large enough to be visible to the unaided eye," as well as the tissue from which they are composed (Standing, 2016, p. 41).

There has been a strong revival of interest in fascia during the past two decades, shown in a steep linear growth in the number of Ovid MEDLINE[®] and Scopus-indexed reports that incorporate the term *fascia* in their title or abstract (Findley et al., 2012a; Wearing et al., 2015). This recent upsurge in scientific attention has been echoed in the staging of five major international Fascia Research Congresses and numerous fascia-focused symposia, a proliferation of new books about fascia and fascial therapies (e.g., Schleip et al., 2012; Guimberteau and Armstrong, 2015; Stecco, 2015), and an unprecedented level of media interest—including television documentaries, webpages and webinars, and

*Correspondence to: Sue Adstrum, 13 Savage Street, Westmere, Auckland 1022, New Zealand. E-mail: sueadstrum@xtra.co.nz

Received 2 March 2019; Accepted 13 March 2019

Published online 1 April 2019 in Wiley Online Library (wileyonlinelibrary.com). DOI: 10.1002/ca.23371

¹This term is still used by anatomists, as in *taeniae coli*, sometimes known as "fasciae of the colon" (Anderson, 2003, p. 674), as well as, *taenia thalami* and *taenia of the fourth ventricle* (flat bands of brain tissue).

audiovisual learning resources (e.g., Fascia Research Society, 2019; Guimberteau, 2019; Hedley, 2019). This raises the possibility that people's understanding of fascia may have changed, and perhaps still be changing, from how it was known in the past. The aim of this review is to survey the anatomical portrayal of fascia through history, in order to help contextualize the ways it is now known.

MATERIALS AND METHODS

Data were obtained from an open-ended search of anatomical, medical, surgical, bioscientific, and body-work literature pertaining to fascia, including (>250 in total) anatomical and medical dictionaries, anatomical nomenclatures, anatomy textbooks, conference proceedings, peer-reviewed journals, and monographs retrieved from the University of Otago's and the authors own library collections, as well as the Early English Books Online, Eighteenth Century Collections Online, and archive.org digital libraries. This inquiry only considers English-language publications and texts that have been translated into English. It is likely much has been written about fascia in other languages, both ancient and modern, that is not discussed here due to the resources available for this study.

Historiographic methodology (Stone, 1981) facilitated development of a socially contextualized narrative about the progression of fascia-related anatomical knowledge but was not used as a specialized means of analysis. Data were analyzed thematically (Braun and Clarke, 2006) to discover how fascia has been successively known since its preliminary description in English medical discourse.

RESULTS

Medical writers have alluded to the body's membranous and tendinous fascial parts since the days of Egypt's Pyramid Age, circa 2,500 BC (Breasted, 1930), ancient Greece, and Rome (Goss, 1963; Longrigg, 1998; Bos, 2004; Potter, 2010). However, what the ancients knew about fascia, and the terminology they used to discuss it, has not been methodically reported in English.

16th–17th Centuries

The word *fascia* appears to have entered English medical discourse with Crooke's (1615) reference to the "*Fasciam* or the swath-band" (p. 922), now known as *thoracolumbar fascia*, and *fasciam latam*, which he later (1651) describes as a "membranous body... [that is] more like a membrane than a tendon" (p. 694). In the absence of contrary evidence (Vicary, 1586; McConchie, 1997), Crooke (1615) was probably one of the earliest, if not the first, English writer to deploy *fascia* as an anatomical expression.

Cowper (1694) relatedly observes that muscles of the "cubit" (forearm) are enclosed by *fascia lata* (p. 3), describes the thigh and leg as being invested with *fascia membranosa* (p. 177), and identifies the "external tendon" of biceps brachii as *fascia tendinosa* (p. 147). He

subsequently claims that the *fascia lata* or *fascia membranosa* of the leg contributes to the annular ligament at the ankle, "like a Bandage that retains [the] Tendons in their proper Situation" (1698, commentary on 80th and 81st tables).

The anatomy textbooks in this era broadly portray the membranes (syn., *membrana*, *integuments*, *coats*, *strata*, *skinnes*, *tunicles*, and *pannicles*) as an interconnected assemblage of soft tissue layers sequentially interposed between the body's skin and bones (Vicary, 1586; Crooke, 1615, 1651; Collins, 1685; Cowper, 1698) collectively forming a universal covering garment or "common Vest" (Collins, 1685, p. 78). Crooke (1651, p. 694–695) observes membranes are "sprinkled through the whole Body almost internally and externally," although the differences between them are "manifold and are taken from their substance, magnitude, site, figure, conformation or texture, & from the nature of the parts which they invest or contain." Despite their seemingly solid appearance, he notes "every membrane is double; through which duplicature run veins for nourishment, arteries to convey life, and Nerves to convey sense" (1651, p. 694).

Crooke taxonomically describes membranes in relation to a hierarchically ordered series of categories (see Table 1), fundamentally distinguishing between *true membranes*, which invest the entire body and its many parts, and their *illegitimate* counterparts, which condense to form a range of fibrous body parts. He explains that there is "an almost infinite number" of *particular membranes* that specifically invest and help "sustain" the body's parts and regions (1651, pp. 694–695).

Membrane, Collins (1685) explains, have "a more tender compage [physical structure] then the substance of Bones, Cartilages, Ligaments and Tendons," and are generally composed of "minute nervous Filaments, finely spun, and curiously interwoven in right [vertical], oblique, and transverse positions; which give great strength to the rare structure of membranes; whereupon they may be several ways extended in length, breadth, and obliquely, without any laceration" (p. iii). Their individual composition varies, although most are "fastened" to their neighbors by "the interposition of many small Fibres, or Membranes" (p. viii).

According to Collins, the *common coat* (or *integument*) of the muscles (syn., *de membrana musculorum communi*) instead "hath a substance transparent and much thinner than the Adiposa," whose interfibrous spaces are "filled up with concreted nervous Liquor." He explains that this "diffusive tunicle" serves to "encircle" and "enwrap" the whole body and its muscles, protect muscles against heat and cold, and maintain muscles in their correct places and to fasten the skin in position (1685, pp. 79–80).

Crooke (1651, pp. 693–694) identifies that the "common office" of the membranes is to collectively act as the "Organ of the sense of touching," due to their demonstrable "tactive qualities" (sensitivity to touch). In contrast, the muscles and organs that they invest are fundamentally insensible, he explains, and the nerves convey but do not detect tactile information. If the membranes are "despoiled," their sensibility is correspondingly reduced.

TABLE 1. Crooke’s (1651) Membrane Classification System

Membranes, or Coats	Embryos & unborn infants <i>Chorion, Amnios, & Allantoides</i>	Invest whole body <i>Skin, Fatty Membrane</i> <i>Fleshy Membrane</i>
	True Membranes	Universal Membranes Invest same kind of parts <i>Common Membrane of the Muscles, Periosteum</i>
	Creatures that have been born	Particular Membranes Invest a body region <i>Pericranium, Pleura, Peritoneum</i> Invest a body part <i>Dura mater & Pia mater, Membranous Coat of Liver, Coats of Eyes</i>
	Illegitimate Membranes, or Membranous Bodies	Ligamentall Membranes & Membranous Ligaments [ligaments & joint capsules] Dilated Tendons of Muscles <i>Fasciam latam</i> Membranous Parts <i>Bladders of Urine and Gall, Stomach, Guts, Wombe</i>

Crooke (1651) comprehensively describes the structural organization of the body’s membranes in relation to a series of taxonomic categories. Italics denote some of his specified examples.

18th Century

At least 10 anatomical terms incorporated *fascia* in their name during this century, although fascia was still often known as *membrane* or *membrana*. *Fascia* also, and possibly more frequently, meant a surgical bandage—such as, *fascia heliodori* or *fascia spiralis repens*. Fascia-alluding terminology progressively appeared in case reports and case studies, books translated from Latin, French, or German, and medical dictionaries. Lacking detailed anatomical explication, fascia was a multifaceted concept that encompassed:

1. A general type of tissue, such as, *aponeurotic fascia* (Winslow, 1733), *membranous fascia* (Albinus, 1777), and *tendinous fascia* (De La Vauguion, 1707);
2. Certain types of fibrous body parts including aponeuroses, broad *bands* of aponeurotic tissue, membranes, *ligamentary expansions*, *muscular ligaments*, *tendinous expansions* (Winslow, 1733), tendons, a *portion* of a tendon (Motherby, 1775), *expansions of muscles* (Hooper, 1797), *fibrous sheaths* (Simmons, 1780), or *vaginas* (Albinus, 1777); and
3. Several specific sections of fascia—for example, *fascia lata* (James, 1743), *fascia lumborum*, the *fascia of the annular ligament* (Motherby, 1775), the *tendinous fascia that covers the bones of the arm* (Simmons, 1780), and the fascia covering a particular muscle, such as temporalis (Hunter, 1771). *Fascia lata*, however, ambiguously referred to the membranous sleeve of the thigh (James, 1743) or entire lower limb (Barrow, 1749), and a hip abductor muscle (e.g., James, 1743), until it was determined that *fascia lata* is “a large Membranous, Tendinous, or Ligamentary Covering,” and the *musculus fasciae latae* is “a small anterior superficial Muscle” (Winslow, 1733, p. 51).

The loose connective tissue—then known as *cellular texture*, *tela cellulosa*, *cellular membrane*, and *cellular substance*—constituting fascia was also much discussed (Wilson, 1944). Cellular texture, named for the many tiny *cells* (open spaces) within its web-like areolar substance, was recognized as a “universal connecting medium” (Simmons, 1780, p. xix) that condenses to form membranes, amasses between contiguous body parts, surrounds nerves and vessels, and infiltrates muscles and organs, seamlessly merging from one form into another. So that, as Haller (1754) explains, in “some parts of the body it is open and loose, being formed of long and distant plates,” whereas in others “it is thin and compact, being made up of short fibres, concreted together” (p. 16). Haller describes the cellular substance as being made up in part of “simple fibrills” and also partly of “an infinite number of little plates or scales, which, joined in various directions intercept small cells and weblike spaces.” By extending around solid parts of the body, they allow “free and ample motion” (1754, p. 10).

Cellular spaces, Haller (1754, p. 17) continues, “hardly ever” contain fat and are “moistened by a watery vapour, that is somewhat gelatinous and oily,

exhaled out by the arteries and received again into the veins.” And, when “the vapour is, by inflammation, too glutinous, or, from any cause, absent or abolished, the contiguous membranes or plates are cemented into one, with a loss of their motion” (Ibid).

According to Wilson (1944), many anatomists at this time, regarded cellular tissue to be “essentially a gelatinous material which only on distention assumes the form of filaments and plates, or which takes on these forms at death by coagulation.” This concept contributed to a late 18th to early 19th century discussion about whether cellular tissue is primarily fibrous or viscous in nature.

19th Century

The 19th century was associated with a marked expansion in fascia-relating anatomical terms defined in medical dictionaries. In 1801, for example, Motherby and Wallis listed five terms prefixed by *fascia*; three of which (*fascia*, *fascia lata*, and *fascia lumborum*) related to fascia and the other two (*fasciae latae musculus* and *fascialis*) corresponded to the muscles now known as *tensor fasciae latae* and *sartorius*. In 1839, Hooper and Grant defined 10 similarly prefaced expressions, 8 pertaining to fascial parts, and 2 to surgical bandages. Duglison and Duglison (1876) recognized 26 fascia-containing anatomical terms, whereas Foster (1892) acknowledged 231. Some dictionary word lists (especially Foster, 1892) were boosted by synonyms, including eponyms (Adstrum, 2015) and non-English names for the same fasciae. A similar pattern of terminological growth is also evident in anatomical textbooks (see Fig. 1). Despite some variability in the terms used by individual authors, this vocabular expansion was principally linked to the discovery of many previously unrecognized sections of fascia and was not artificially inflated by synonymous and non-English word use.

Most newly identified fasciae were named for their topographic location, physical appearance, tissue type, perceived propriety, or function. For instance, the terms *superficial fascia* and *deep fascia* signaled the relative nearness of these fasciae to the skin and *intermuscular fascia* its interposition between muscles. *Fascia lumborum* and *cervical fascia* proclaimed their regional location, whereas *cremasteric fascia* and *temporal fascia* proclaimed their proximity to a certain muscle. *Cribri-form* (sieve-like), *infundibuliform* (funnel-shaped), and *triangular* fasciae related to their physical appearance, while others—including *areolo-fibrous fascia*, *aponeurotic fascia*, and *fascia adiposa renum*—identified the tissue they are made of. Sir Astley Cooper purportedly coined *fascia propria* to distinguish “the proper cellular envelop [sic] of a hernial sac” (Hooper and Grant, 1839), although this term was soon generalized to the thick membranes now known as *deep fascia* (e.g., Ellis, 1840). Again, the *fasciae of origin*, which “serve for the origin of muscles” (Foster, 1892), linguistically linked structure with function.

Fascia was now predominantly portrayed as a membranous body part or as the aponeurotic expansion of a muscle. Lexicographers frequently identified *aponeurosis*

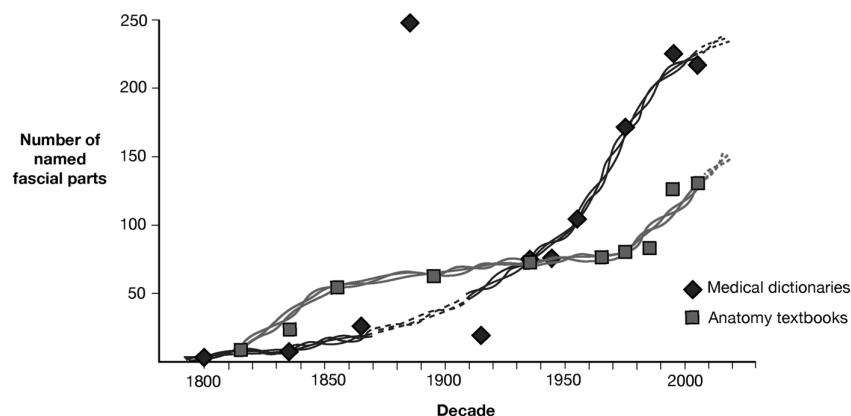


Fig. 1. Expansion in fascia-relating terminology used in 19th to 21st century medical dictionaries and anatomy textbooks. The number of fascial terms used in medical dictionaries (diamonds) and anatomy textbooks (squares) continued to increase throughout this period.

and *fascia* as synonyms (e.g., Motherby and Wallis, 1801), and described *fasciae* as “the tendinous expansions of muscles which bind parts together” (Hooper and Grant, 1839, p. 614). *Fascia* was similarly construed in most anatomy textbooks. Bichat (1822b) distinguished between *fasciae* (ligaments and tendons) and membranes (fibrous membranes, fibrous capsules, fibrous sheaths, and aponeuroses). Membranes are, he asserted, “broad and thin organ[s],” whereas *fasciae* are relatively “longer and thicker” (p. 260). He also recognized that the body’s many fibrous organs are “almost all continuous and connected,” despite their disparate morphologies (p. 263).

By the mid-19th century, *fasciae* were usually categorized in two groups, distinguished by their tissue type (e.g., Wilson, 1851) and their relative closeness to the skin. The (i) *fibro-areolar fascia*, “found immediately beneath the integument over almost the entire surface of the body [and] generally known as the *superficial fascia*,” and the (ii) *aponeurotic or deep fascia*, “a dense inelastic and unyielding fibrous membrane, forming sheaths for the muscles, and affording them broad surfaces for attachment” (Gray, 1858, pp. 186–187).

This widely adopted approach to classify *fasciae* effectively distinguished them from cellular tissue (syn. *areolar tissue*, *cellular texture*, *fibro-areolar tissue*, *fibrocellular tissue*, *mucous texture*), which Bichat, for instance, separately identified as the *cellular system* (syn. *cribriform body*). He describes the cellular system as a complex “assemblage of filaments, and of white soft layers, intermixed and interwoven in different ways” leaving open spaces between them that “serve as a reservoir for fat and serum.” This system, he explains, is “everywhere spread, is everywhere continuous” (Bichat, 1822a, p. 87).

The color and strength of the relatively robust *fasciae* were attributed to its white fibers, which Wilson (1851, p. 115) explains are “cylindrical, exceedingly minute (about 1/15000th of an inch in diameter), transparent and undulating.” The fibers are collected

into small and larger fasciculi, which “give rise to the production of thin laminæ, membranes, ligamentous bands, and tendinous cords” (Ibid).

20th Century

Fascia-relating terminology continued to expand (see Fig. 1) due to a variety of factors, including increasingly specific naming of some *fasciae* (e.g., *hypothenar fascia*, *pharyngobasilar fascia*, and *retropancreatic duodenal fascia*), lexicographers identifying *fasciae* in English and Latin, and a late-century coining of terms (e.g., *endopelvic fascia/fascia endopelvina*, *fasciae of muscles/fasciae musculorum*, *investing fascia*, and *visceral fascia/fascia visceralis*) associated with nomenclatural standardization (Federative Committee on Anatomical Terminology [FCAT], 1998). Several terms emerged in surgical literature—such as, *fascial planes* (regional and surgical), *fascial spaces*, and *fascial systems*. Aside from ongoing word revisions (additions, omissions, and changes in name), the net number of body parts with *fascia* in their name remained relatively static (averaging 45) in the 1955, 1961, 1966, 1977, 1983, and 1989 nomenclature lists developed under the auspices of the International Federation of Associations of Anatomists.

Fascia was a recognized anatomical term, yet there was some international inconsistency about which body parts were recognized as *fasciae* and the names by which they were known (Wendell-Smith, 1997; FCAT, 1998). Medical dictionaries generally defined *fascia* as a “sheet or band of fibrous tissue which covers the body under the skin and invests the muscles and certain organs” (Miller, 1947, p. 538). Yet, as Hollinshead (1954, p. 282) explains, “there is no generally accepted definition as to how dense connective tissue must be before it can be regarded as forming a *fascia*, and... fascial spaces are simply areas of relatively loose connective tissue.” Others, including Le Gros Clark (1945) intrinsically regarded all loose

connective tissue as fascia, noting this “material varies considerably in its consistency, in some places forming a very delicate retinaculum of loose texture, and in other places becoming condensed into a firmly woven feltwork or into tough fibrous sheets” (p. 31).

The custom of applying “a specific local term to any aggregation of connective tissue, sizeable enough to dissect” was challenged (Warwick and Williams, 1973) p. 490) by anatomists who observed that fascial tissue (*syn. areolar tissue, connective tissue, fibrous tissue*) and fascia are innately continuous. It was argued that “the existence of a certain fascia may largely be a question of semantics” (Rosse and Goddum-Rosse, 1997, p. 21), as “all connective tissue is continuous with all other connective tissue.” So, from this viewpoint, “a fascia has no beginning and no end” (Ibid).

From a gross anatomical viewpoint, fascia seems to have mainly been perceived as a relatively unimportant body part that simply “covers and invests all the so-called higher structures” (Gallaudet, 1931, p. 1). Individual exceptions notwithstanding (e.g., Gallaudet,

1931; Stilwell, 1957) relatively few research reports pertained to the gross anatomical description of fascia. Most instead applied their findings about fascia’s structure and physical properties to contemporary clinical advancement of medicine and surgery (e.g., Orrin, 1928; Bogduk and Macintosh, 1984). As the century progressed, connective tissue was increasingly also described by other disciplines including histology, physiology, and structural biology.

21st Century

During the first decade of the 21st century, fascia became the focus of an emergent, interdisciplinary field of basic and applied scientific interest that has noticeably gained momentum since the inaugural Fascia Research Congress was hosted by Harvard Medical School in 2007 (Benjamin, 2009; Wearing et al., 2015). The conference was preceded by the release of a holistic definition of fascia that incorporated several

TABLE 2. Varying 21st century definitions of fascia

Source	Definition
Federative International Programme on Anatomical Terminologies (2011, p. 33) Standring (2016, p. 41)	Fascia consists of sheaths, sheets or other dissectible connective tissue aggregations... [It] includes not only the sheaths of muscles but also the investments of viscera and dissectible structures related to them. Fascia is a generic term applied to sheaths, sheets or other dissectible masses of connective tissue that are large enough to be visible to the unaided eye.
Anderson (2012, p. 679)	Fascia [is] a sheet or band of fibrous tissue such as lies deep to the skin or forms an investment for muscles and various other organs of the body.
Findley and Schleip (2007, p. 2)	Fascia is the soft tissue component of the connective tissue system that permeates the human body forming a whole-body continuous three-dimensional matrix of structural support. It interpenetrates and surrounds all organs, muscles, bones and nerve fibers, creating a unique environment for body systems functioning. The scope of our definition and interest in fascia extends to all fibrous connective tissues, including aponeuroses, ligaments, tendons, retinacula, joint capsules, organ and vessel tunics, the epineurium, the meninges, the periosteum, and all the endomysial and intermuscular fibers of the myofasciae.
Kumka and Bonar (2012)	Fascia is an uninterrupted viscoelastic tissue which forms a functional 3-dimensional collagen matrix. It surrounds and penetrates ... and is virtually inseparable from... all structures of the body extending from head to toe, thus making it difficult to isolate and develop its nomenclature.
Stecco and Schleip (2016)	A fascia [is] a sheath, a sheet or any number of dissectible aggregations of connective tissue that forms beneath the skin to attach, enclose, separate muscles and other internal organs.
Adstrum et al. (2017) and Stecco et al. (2018)	The fascial system consists of the three-dimensional continuum of soft, collagen containing loose and dense fibrous connective tissues that permeate the body. It incorporates elements such as adipose tissue, adventitia and neurovascular sheaths, aponeuroses, deep and superficial fasciae, epineurium, joint capsules, ligaments, membranes, meninges, myofascial expansions, periosteum, retinacula, septa, tendons, visceral fasciae, and all the intramuscular and intermuscular connective tissues including endo-/peri-/epimysium. The fascial system surrounds, interweaves between, and interpenetrates all organs, muscles, bones and nerve fibers, endowing the body with a functional structure, and providing an environment that enables all body systems to operate in an integrated manner.

These definitions incorporate several overlapping yet different sets of meaning, each of which has been developed within a particular context and with certain interests in mind. Together, they collectively represent two very different ways of conceptualizing fascia i.e., reductionist-descriptive-structural (anatomical) and holistic-heuristic-functional (interdisciplinary), so are not entirely congruent with each other

fibrous parts (e.g., aponeuroses, ligaments, tendons, retinacula, and joint capsules) that have at times been depicted as existing separately from fascia (Findley and Schleip, 2007). This understanding, in which fascia and fascial tissue are not hypothetically set apart (see Table 2), appears to conceptually underpin much contemporary fascia research.

Literature associated with this developing research arena broadly relates to the human fascial system's molecular through to organismic levels of structural, physical, and dynamic properties, functioning, health, pathology, and remedial treatment (see Benjamin, 2009; Stecco et al., 2011; Findley et al., 2012b; Kumka and Bonar, 2012; Zügel et al., 2018; Gonzalez et al., 2018). The multiple-discipline-spanning nature of this work is reflected in the coinage of many new terms including, for instance, *epimysial fascia*, *fasciocyte*, *fascial architecture*, *fasciatome*, *myofascial expansion*, and *myofascial meridian* (see Schleip et al., 2012; Stecco, 2015).

DISCUSSION

A considerable amount has been learned about fascia during the past four centuries, although it has not always been known by this name. Fascia has been variously recognized, named, described, and discussed. This multifaceted body part has been overlappingly epitomized as: interconnecting sheets and layers of body-swathing membranes, an inconstant range of ostensibly distinct parts (fasciae and fibrous structures), several forms of connective tissue, and a body-wide soft connective tissue system.

From a poststructural perspective, plurality and time-based change in the ways people conceptualize and medically engage with the body, and its parts, is normal. It may be expected that various groups of people will espouse different understandings of fascia, which are likely to change with the passage of time. In practice, the concurrent existence of multiple meanings can be problematic (Wendell-Smith, 1997; Langevin and Huijing, 2009), especially to those who are familiar with, and may be aware of, only one viewpoint.

History shows that fascia has been anatomically explained from a range of angles, each of which relates to the epistemic environment of its time. Different sets of anatomical knowledge are shaped "in varying proportions and in different ways," by the modes of "observation, therapeutic experience, textual tradition, philosophical ideas, and cultural imagination" that currently prevail within the society in which it was developed (Siraisi, 1995).

Fascia's anatomical depiction appears to have evolved in tandem with advances in technology. Wearing et al. (2015) attribute recent advances in fascia research, at least in part, to innovative research methods, which now include, new histological and immunohistochemical staining techniques, hydrodissection, mechanical tissue indentation devices, modern imaging systems, plastination, and virtual modeling. These techniques are revealing fresh insights into the morphology of fascia that expand on those formerly garnered through theoretical argument, experimental physical procedures

(e.g., boiling, exposure to air and heat, maceration, and putrefaction), macroscopic observation of dissected cadavers, and vivisection.

The defined (i.e., currently interpreted) meaning of fascia will influence what parts are anatomically examined and described, and are subsequently built into downstream explanation about how the body and its parts (including the fascial ones) seem to work and how they may contribute to, and are affected by, the overall functioning of the body in states of health and impairment. The widespread 20th-century characterization of fascia as an indefinite and relatively undifferentiated body part, for instance, is likely to have been associated with it being routinely *cleaned* away (i.e., destroyed and removed) during anatomical dissection. Conversely, fascia's escalating depiction as a complex, global connective tissue system is connected to it being more expansively described in a multiple-discipline-spanning research environment.

Following Heidegger (1977), the word *technology* may be interpreted to include the epistemic principles that expressly form the scaffolding of every research study. For example, before the 18th century, arrival of the European Age of Enlightenment, medical doctrine was fundamentally premised on humoral theory, that is, belief that temperament and health are reliant on the evenly balanced flow of four etheric fluids—the *humors*. This philosophical perspective is conceivably linked to the explanation that cellular tissue contains "coagulated sulphureous matter" (Collins, 1685, p. viii) or is "moistened by a watery vapour" (Haller, 1754, p. 17). Some of these ideas are possibly being reiterated by current investigation of subtle bioelectromagnetic and interstitial fluid flows in interstitial fascial tissue (e.g., Stefanov et al., 2013; Benias et al., 2018).

Each and every set of fascia-related knowledge contributes to a cumulative understanding of fascia. None of them, however, can explain fascia in its entirety. This raises the question of how to constructively deal with the existence of several different sets of fascia-related knowledge. Do we regard them as coexisting alongside, competing with, or complementary to each other? Simply gathering information and learning more about them may be professionally sufficient for some. Others may prefer to combine several sets of information to develop more complex, and possibly richer, integrative anatomical understandings of fascia. The latter already appears to have begun, to a variable extent, within the nascent interdisciplinary fascia research environment.

ACKNOWLEDGMENTS

This report is based on S.A.'s doctoral research at the University of Otago, New Zealand. The authors declare that there are no conflicts of interest.

REFERENCES

- Adstrum S. 2015. Fascial eponyms may help elucidate terminological and nomenclatural development. *J Bodyw Mov Ther* 19:516–525.
- Adstrum S, Hedley G, Schleip R, Stecco C, Yucesoy C. 2017. Defining the fascial system. *J Bodyw Mov Ther* 21:173–177.

- Albinus BS. 1777. *Tables of the Skeleton and Muscles of the Human Body*. London: John and Paul Knapton. p 92.
- Anderson DM, (ed.). 2003. *Dorland's Illustrated Medical Dictionary*. 30th Ed. Philadelphia, PN: Elsevier Saunders. p 2190.
- Anderson DM, (ed.). 2012. *Dorland's Illustrated Medical Dictionary*. 32nd Ed. Philadelphia, PN: Elsevier Saunders. p 2147.
- Barrow J. 1749. *Dictionarium Medicum Universale: Or, a New Medical Dictionary*. In: Longman R, Hitch C, Millar A, editors. London. p 588.
- Benias PC, Wells RG, Sackey-Abagye B, Klaven H, Reidy J, Buonocore D, Miranda M, Kornacki S, Wayne M, Carr-Locke DL, Theise ND. 2018. Structure and distribution of an unrecognized interstitium in human tissues. *Sci Rep* 8:4947. <https://doi.org/10.1038/s41598-018-23062-6>.
- Benjamin M. 2009. The fascia of the limbs and back—A review. *J Anat* 214:1–18.
- Bichat X. 1822a. *General Anatomy, Applied to Physiology and Medicine*, Translated from the French by George Hayward. Vol. 1. Boston, MA: Richardson and Lord. p 468.
- Bichat X. 1822b. *General Anatomy, Applied to Physiology and Medicine*, Translated from the French by George Hayward. Vol. 2. Boston, MA: Richardson and Lord. p 436.
- Bogduk N, Macintosh JE. 1984. The applied anatomy of the thoracolumbar fascia. *Spine J* 9:164–170.
- Bos G. 2004. *Maimonides: Medical Aphorisms*. Treatises 1–5. Provo, UT: Brigham Young University Press. p 156.
- Braun V, Clarke V. 2006. Using thematic analysis in psychology. *Qual Res Psychol* 3:77–101.
- Breasted JH. 1930. *The Edwin Smith Surgical Papyrus*. Vol. 1. Chicago, IL: The University of Chicago Press. p 507.
- Collins S. 1685. *Systeme of Anatomy*. Vol. 1. London: Robert Midgley. p 678.
- Cowper W. 1694. *Myotomia Reformata: Or, a New Administration of all the Muscles of Humane Bodies*. London: Sam Smith and Ben Walford. p 166.
- Cowper W. 1698. *The Anatomy of Humane Bodies, with Figures Drawn after the Life by some of the Best Masters in Europe*. London: Sam Smith and Ben Walford. p 386.
- Crooke H. 1615. *Mikrokosmographia: A Description of the Body of Man Together with the Controversies and Figures Thereto Belonging*. London: William Iaggard.
- Crooke H. 1651. *Mikrokosmographia: A Description of the Body of Man Together with the Controversies and Figures Thereto Belonging*. 2nd Ed. London: John Clarke. p 766 [Orig. printed in 1631 for Michael Sparke].
- De La Vauguion M. 1707. *A Compleat Body of Chirurgical Operations, Containing the Whole Practice of Surgery with Observations and Remarks on each Case*. In: Bonwick R, Tonson J, Freeman W, Tim Goodwin J, Walthoe MW, Nicholson F, Newborough T, Yook B, Manship S, Parker R, editors. London. p 447.
- Dunglison R, Dunglison RJ. 1876. *A Dictionary of Medical Science*. 2nd Ed. London: J. & A. Churchill. p 1131.
- Ellis GV. 1840. *Demonstrations of Anatomy: A Guide to Dissection of the Human Body*. London: Taylor and Walton. p 768.
- Fascia Research Society. 2019. Resources. URL: <https://fasciaresearchsociety.org/resources> [accessed Jan. 2019]
- Federative Committee on Anatomical Terminology [FCAT] (eds.). 1998. *Terminologia Anatomica: International Anatomical Terminology*. New York: Thieme. p 292.
- Federative International Programme on Anatomical Terminologies (eds.). 2011. *Terminologia Anatomica: International Anatomical Terminology*. 2nd Ed. Stuttgart: Georg Thieme Verlag. p 292.
- Findley T, Schleip R. 2007. Introduction. In: Findley TW, Schleip R, editors. *Fascia Research: Basic Science and Implications for Conventional and Complementary Health Care*. Munich: Elsevier. p 2–9.
- Findley T, Chaitow L, Schleip R. 2012a. Introduction. In: Chaitow L, Findley TW, Schleip R, editors. *Fascia Research III: Basic Science and Implications for Conventional and Complementary Health Care*. Munich: Elsevier. p 1–11.
- Findley T, Chaudry H, Stecco A, Roman M. 2012b. Fascia research—A narrative review. *J Bodyw Mov Ther* 16:67–75.
- Foster FP. 1892. *An Illustrated Encyclopædic Medical Dictionary*. Vol. 3. New York: D. Appleton and Company. p 1545–1547.
- Gallaudet BB. 1931. *A Description of the Planes of Fascia of the Human Body: With Special Reference to the Fascia of the Abdomen, Pelvis and Perineum*. New York: Columbia University Press. p 90.
- Glare PGW, (ed.). 1982. *Oxford Latin Dictionary*. Oxford: The Clarendon Press. p 677.
- Gonzalez CAA, Driscoll M, Schleip R, Wearing S, Jacobson E, Findley T, Klinger W. 2018. Frontiers in fascia research. *J Bodyw Mov Ther* 22:873–880.
- Goss CM. 1963. On the anatomy of muscles for beginners by Galen of Pergamon. *Anat Rec* 145:477–501.
- Gray H. 1858. *Anatomy: Descriptive and Surgical*. London: John W. Parker and Son. p 750.
- Guimberteau, JC. 2019. Videos. URL: <http://www.guimberteau-jc-md.com/en/videos.php> [accessed Jan. 2019].
- Guimberteau JC, Armstrong C. 2015. *Architecture of Human Living Fascia: The Extracellular Matrix and Cells Revealed through Endoscopy*. Edinburgh: Handspring Publishing. p 204.
- Haller AV. 1754. *Dr. Albert Haller's Physiology; Being a Course of Lectures upon the Visceral Anatomy and Vital Oeconomy of Human Bodies*. Vol. 1. [S. Mihles, Trans.]. London: W. Innys and J. Richardson. p 339.
- Hedley G. 2019. The integral anatomy series. URL: <https://www.youtube.com/playlist?list=PLQRL-IRQdb5iiox5vBd8kfcXumHMYN2XU> [accessed Jan. 2019].
- Heidegger M. 1977. *The Question Concerning Technology and Other Essays*. New York, NY: Harper & Row. p 182.
- Hollinshead WH. 1954. *Anatomy for Surgeons: The Head and Neck*. Vol. 1. London: Cassell and Company Limited. p 560.
- Hooper R. 1797. *The Anatomist's Vade-Mecum: Containing a Concise and Accurate Description of the Structure, Situation, and Use of Every Part of the Human Body*. London: Bell. p 182.
- Hooper R, Grant K. 1839. *Lexicon Medicum or Medical Dictionary*. 7th Ed. London: Longman, Orme, and Co. p 1408.
- Hunter J. 1771. *The Natural History of the Human Teeth: Explaining their Structure, Use, Formation, Growth, and Diseases*. London: J Johnson. p 19.
- James R. 1743. *A Medicinal Dictionary*. Vol. 2. London: T Osborne. p 592–1181.
- Kumka M, Bonar J. 2012. Fascia: A morphological description and classification system based on a literature review. *J Can Chiro Assoc* 56:179–191.
- Langevin HM, Huijing PA. 2009. Communicating about fascia: History, pitfalls, and recommendations. *Int J Ther Massage Bodywork* 2:3–8.
- Le Gros Clark WE. 1945. *The Tissues of the Body: An Introduction to the Study of Anatomy*. Oxford: Clarendon Press. p 415.
- Lewis CT, Short C. 1966. *A Latin Dictionary*. London: Oxford University Press. p 726.
- Liddell H., Scott R, Jones H., McKenzie R. 2011. The online Liddell-Scott-Jones Greek-English lexicon. URL: <http://www.tig.uci.edu/ljsj> [accessed Jan. 2016].
- Longrigg J. 1998. *Greek Medicine: From the Heroic to the Hellenistic Age*. London: Gerald Duckworth & Co. Ltd. p 256.
- McConchie RW. 1997. *Lexicography and Physicke: The Record of Sixteenth-Century English Medical Terminology*. Oxford: Clarendon Press. p 448.
- Miller ECL, (ed.). 1947. *The American Illustrated Medical Dictionary*. 21st Ed. Philadelphia, PN: W.B. Saunders Company. p 538.
- Motherby G. 1775. *A New Medical Dictionary; Or, General Repository of Physic*. London: J Johnson. p 610 unnumbered.
- Motherby G, Wallis G. 1801. *A New Medical Dictionary, or General Repository of Physic*. London: J. Johnson 811 p.
- Orrin HC. 1928. *Fascial Grafting in Principle and Practice: An Illustrated Manual of Procedure and Technique*. Edinburgh: Oliver and Boyd. p 92.
- Potter P. 2010. *Hippocrates*. Vol. 9. Boston, MA: Harvard University Press. p 397.

870 Adstrum and Nicholson

- Rosse C, Goddum-Rosse P. 1997. *Hollinshead's Textbook of Anatomy*. 5th Ed. Philadelphia, PA: Lipponcott-Raven Publishers. p 912.
- Schleip R, Findley TW, Chaitow L, Huijing PA, (eds.). 2012. *Fascia: The Tensional Network of the Human Body*. Edinburgh: Churchill Livingstone Elsevier. p 566.
- Simmons SF. 1780. *The Anatomy of the Human Body*. Vol. 1. London: J. Murray. p 484.
- Simpson JA, Weiner ESC, (eds.). 1989. *The Oxford English Dictionary*. Vol. 5. 2nd Ed. Oxford: Clarendon Press. p 740.
- Siraisi NG. 1995. Early anatomy in comparative perspective: Introduction. *J Hist Med Allied Sci* 50:3–10.
- Standing S, (ed.). 2016. *Gray's Anatomy: The Anatomical Basis of Clinical Practice*. 41st Ed. Edinburgh: Churchill Livingstone. p 1562.
- Stecco C. 2015. *Functional Atlas of the Human Fascial System*. Edinburgh: Churchill Livingstone. p 374.
- Stecco C, Schleip R. 2016. A fascia and the fascial system. *J Bodyw Mov Ther* 20:139–140.
- Stecco C, Macchi V, Porzionato A, Duparc F, De Caro R. 2011. The fascia: The forgotten structure. *Ital J Anat Embryol* 116:127–138.
- Stecco C, Adstrum S, Hedley G, Schleip R, Yucesoy CA. 2018. Update on fascial nomenclature. *J Bodyw Mov Ther* 22:354.
- Stefanov M, Potroz KJ, Lim J, Cha R, Nam MH. 2013. The primo vascular system as a new anatomical system. *J Acupunct Meridian Stud* 2013 6:331–338.
- Stilwell DL. 1957. Regional variations in the innervation of deep fasciae and aponeuroses. *Anat Rec* 127:635–653.
- Stone L. 1981. *The Past and the Present*. Boston, MA: Routledge & Kegan Paul. p 274.
- Vicary T. 1586. *The Englishmans Treasure, or Treasure for Englishmen with the True Anatomye of Mans Body*. London: John Perin. p 109.
- Warwick R, Williams PL, (eds.). 1973. *Gray's Anatomy*. 35th Ed. London: Longman. p 1471.
- Wearing SC, Schleip R, Chaitow L, Klingler W, Findley T, (eds.). 2015. *Fascia research 2015—State of the art. Fascia Research IV: Basic Science and Implications for Conventional and Complementary Health Care*. Munich: Kiener. p 1–13.
- Wendell-Smith CP. 1997. Fascia: An illustrative problem in international terminology. *Surg Radiol Anat* 19:273–277.
- Wilson E. 1851. *The anatomist's Vade Mecum: A System of Human Anatomy*. 5th Ed. London: John Churchill. p 682.
- Wilson JW. 1944. Cellular tissue and the dawn of the cell theory. *Isis* 35:168–173.
- Winslow JB. 1733. *An Anatomical Exposition of the Structure of the Human Body*. Vol. 1. [G. Douglas, Trans.]. London: N. Prevost. p 355.
- Zügel M, Maganaris CN, Wilke J, Jurkat-Rott K, Klingler W, Wearing SC, Findley T, Barbe MF, Steuinacker JM, Vbleeming A, Bloch W, Schleip R, Hodges PW. 2018. Fascial tissue research in sports medicine: from molecules to tissue adaptation, injury and diagnosis. *Br J Sports Med* 52:1–9.